



THE  
SURGICAL CLINICS  
OF  
NORTH AMERICA

JUNE, 1924  
*VOLUME 4 — NUMBER 3*  
CHICAGO NUMBER

PHILADELPHIA AND LONDON  
W. B. SAUNDERS COMPANY

---

COPYRIGHT, 1924, W. B. SAUNDERS COMPANY. ALL RIGHTS RESERVED.  
PUBLISHED BI-MONTHLY (SIX NUMBERS A YEAR), BY W. B. SAUNDERS COMPANY, WEST WASHINGTON  
SQUARE, PHILADELPHIA.

MADE IN U S A



# CONTRIBUTORS TO THIS NUMBER

- MAURICE A. BERNSTEIN, M. D., Attending Orthopedic Surgeon, Michael Reese Hospital.
- RALPH BOERNE BETTMAN, M. D., Consulting Surgeon, Chicago-Winfield Tuberculosis Sanitarium, Adjunct Attending Surgeon, Michael Reese Hospital, Clinical Assistant Surgeon, Northwestern University Medical School.
- ARTHUR DEAN BEVAN, M. D., Professor of Surgery, Rush Medical College, in Affiliation with the University of Chicago, Surgeon to the Presbyterian Hospital.
- LEON BLOCH, M. D., Assistant Professor of Medicine, Rush Medical College.
- FREDERICK CHRISTOPHER, M. D., Assistant Surgeon, St. Luke's Hospital, Junior Surgeon, Evanston Hospital, Evanston, Illinois; Assistant in Surgery, University of Illinois Medical School.
- ARTHUR H. CURTIS, M. D., Clinical Professor of Gynecology, Northwestern University Medical School, Gynecologist, St. Luke's Hospital.
- DANIEL N. EISENDRATH, M. D., Attending Surgeon, Cook County and Michael Reese Hospitals, Head of Urological Department of the Chicago Memorial Hospital; Assistant Clinical Professor of Surgery (Genito-urinary), Rush Medical College.
- JOSEPH FRIEDMAN, M. D., Associate Professor of Medicine, Northwestern University Medical School.
- J. P. GREENHILL, M. D., Alternate Attending Obstetrician, The Chicago Lying-in Hospital and Dispensary, Instructor in Obstetrics, The Northwestern University Medical School.
- WILLIAM M. HARSHA, M. D., Professor of Surgery, College of Medicine, University of Illinois, Attending Surgeon, St. Luke's Hospital.
- HAROLD E. JONES, M. D., St. Luke's Hospital.
- PHILIP H. KREUSCHER, M. D., Professor of Clinical Orthopedic Surgery, Loyola University Medical School, Senior Attending Surgeon, Mercy Hospital.
- PHILIP LEWIN, M. D., Assistant Professor of Orthopedic Surgery, Northwestern University Medical School, Attending Orthopedic Surgeon, Cook County Hospital; Junior Attending Orthopedic Surgeon, St. Luke's Hospital.
- HUGH N. MACKECHNIE, M. D., Professor of Surgery, Post-Graduate Medical School; Attending Surgeon, Post-Graduate, Illinois Masonic and South Shore Hospitals.
- GOLDER LEWIS McWHORTER, M. D., Assistant Clinical Professor of Surgery, Rush Medical College, Assistant Attending Surgeon, Presbyterian Hospital.
- EDWIN M. MILLER, M. D., Assistant Professor of Clinical Surgery, Rush Medical College; Assistant Attending Surgeon, Presbyterian and Children's Memorial Hospitals.
- CHARLES LOUIS MIX, M. D., Professor and Head of the Department of Medicine, Loyola University School of Medicine; Senior Attending Physician, Mercy Hospital, Consulting Physician, Misericordia Maternity Hospital.
- EDWARD LOUIS MOORHEAD, M. D., Professor and Head of the Department of Surgery, Loyola University School of Medicine; Chief of Staff and Senior Attending Surgeon, Mercy Hospital; Consulting Surgeon, Misericordia Maternity and Oak Park Hospitals.
- LOUIS D. MOORHEAD, M. D., Dean and Associate Professor of Surgery, Loyola University School of Medicine; Senior Attending Surgeon, Mercy Hospital and Mercy Clinic.
- ALBERT J. OCHSNER, M. D., Surgeon-in-Chief, St. Mary's and Augustana Hospitals, Professor of Surgery, College of Medicine, University of Illinois.
- LEROY HENDRICK SLOAN, M. D., Internist, Illinois Central Hospital; Instructor in Medicine, Northwestern University Medical School.
- KELLOGG SPEED, M. D., Assistant Professor of Surgery, Rush Medical College; Attending Surgeon, Presbyterian, Cook County, and Provident Hospitals.
- DAVID C. STRAUS, M. D., Assistant Clinical Professor of Surgery, Rush Medical College; Attending Surgeon, Cook County Hospital; Associate Attending Surgeon, Michael Reese Hospital, Director of the Surgical Department, Michael Reese Dispensary.
- ALFRED A. STRAUSS, M. D., Associate Attending Surgeon, Michael Reese and Chicago Lying-in Hospitals.
- THOMAS J. WATKINS, M. D., Professor of Gynecology, Northwestern University Medical School; Senior Gynecologist, St. Luke's Hospital.

U. M. S. Medical College, Jaipur.

LIBRARY.

# CONTENTS

	PAGE
<i>Clinic of Dr. Arthur Dean Bevan, Presbyterian Hospital</i>	
CARCINOMA OF THE COLON	509
A GROUP OF ABDOMINAL TUMORS IN WHICH THE DIAGNOSIS IS DIFFICULT	605
<i>Clinic of Dr. Albert J. Ochsner, Augustana Hospital</i>	
THE TREATMENT OF CASES SUFFERING FROM CANCER WITH THE ACTUAL CAUTERY	619
<i>Clinic of Dr. Thomas J. Watkins, St. Luke's Hospital</i>	
HIGH RECTOCELE	627
<i>Clinic of Dr. Daniel N. Eisendrath, Michael Reese Hospital</i>	
CONGENITAL STRICTURES OF THE URETER	635
<i>Clinic of Dr. Kellogg Speed, Presbyterian Hospital</i>	
TRAUMATIC LESIONS OF THE HEAD OF THE RADIUS RELATION TO ELBOW-JOINT DYSFUNCTION	651
<i>Clinic of Drs. Alfred A. Strauss, Joseph Friedman, and Leon Bloch, Michael Reese Hospital</i>	
COLECTOMY FOR ULCERATIVE COLITIS	667
<i>Clinic of Drs. Edward L. and Louis D. Moorhead and Charles Louis Mix, Mercy Hospital</i>	
THE THYROID GLAND	687
<i>Clinic of Dr. Arthur H. Curtis, St. Luke's Hospital</i>	
THE SELECTION OF ANESTHETICS FOR PLASTIC SURGERY AND SURGERY OF THE LOWER ABDOMEN	709
<i>Clinic of Dr. Golder L. McWhorter, Presbyterian Hospital</i>	
CHRONIC APPENDICULAR COLIC WITH ASSOCIATED STOMACH SYMPTOMS	715
<i>Clinic of Dr. David C. Straub, Michael Reese Hospital</i>	
BRODIE'S ABSCESS	721
<i>Clinic of Dr. Philip H. Kreuzer, Mercy Hospital</i>	
CENTRAL DISLOCATION OF THE HEAD OF THE LEFT FEMUR WITH SUBSEQUENT DISEASE OF THE ACETABULUM DUE TO CONGENITAL LUTIC INFECTION	737
<i>Clinic of Dr. William M. Harsha, St. Luke's Hospital</i>	
CARCINOMA	745
<i>Clinic of Dr. Edwin M. Miller, Presbyterian Hospital</i>	
LESIONS OF THE BREAST ASSOCIATED WITH A DISCHARGING NIPPLE	757
<i>Clinic of Dr. Hugh N. MacKechnie, Post-Graduate Hospital</i>	
METASTATIC HYPERNEPHROMA OF THE FEMUR PRODUCING SPONTANEOUS FRACTURE	765
<i>Clinic of Dr. LeRoy H. Slonik, Illinois Central Hospital</i>	
IDIOPATHIC DILATATION OF THE ESOPHAGUS	773
<i>Clinic of Drs. Harold E. Jones and Philip Lewin, St. Luke's Hospital</i>	
BILATERAL CHARCOT KNEES	783
<i>Clinic of Dr. Frederick Christopher, Evanston Hospital</i>	
SEVERE SPREADING CARBUNCULAR INFECTION OF CHEST WALL FOLLOWING RIB RESECTION UNDER LOCAL ANESTHESIA	795
<i>Clinic of Dr. J. P. Greenhill, Chicago Lying-in Hospital</i>	
THE DYSTROPHIA DYSTOCIA SYNDROME AS AN INDICATION FOR CESAREAN SECTION	811
<i>Clinic of Dr. Ralph Boerne Bettman, Michael Reese Hospital</i>	
CHRONIC EMPYEMA	831
<i>Clinic of Dr. Maurice A. Bernstein, Michael Reese Hospital</i>	
STABILIZING OPERATION FOR PARALYTIC FEET	879

# THE SURGICAL CLINICS OF NORTH AMERICA

---

---

Volume 4

Number 3

---

---

CLINIC OF DR. ARTHUR DEAN BEVAN

PRESBYTERIAN HOSPITAL

---

## CARCINOMA OF THE COLON

Patient Presenting the Picture of a Pseudomyxomatous Peritonitis. At Operation a Large Ovarian Cyst is Found to be the Cause of this Condition. An Interesting Problem in Pathology Presented by Cases of this Character. x-Ray as a Valuable Aid in the After-treatment.

Carcinoma of the Colon in a Man of Fifty. Resection and Side-to-side Anastomosis Between Ileum and Colon. After-management—Necessity for Introducing Fluids After Such Operations.

I HAVE 2 cases to operate upon this morning, both of them rather difficult problems, and both of which have developed in the service of my colleague, Dr. B. W. Sippy.

The first patient is a woman of fifty who had been under Dr. Sippy's observation for several weeks. She came in with a distention of the abdomen which on percussion gave one the sensation of an ascites. A general examination of the patient failed to reveal any heart lesion or kidney lesion or lesion of the liver which might account for the accumulation of fluid in the abdomen. She has had a little temperature and the possibility of tuberculous peritonitis has been considered. The other day Dr. Sippy, after a careful physical examination of the abdomen and convincing himself that there was fluid in the general peritoneal cavity, introduced a good-sized trocar and drew off some very thick gelatinous material through the

trocar, the same sort of material as is characteristic of the condition known as pseudomyxomatous peritonitis. He at once thought of the possibility of a ruptured ovarian tumor, or this condition of pseudomyxomatous peritonitis, which is sometimes associated with myxomatous disease of the appendix or some other portion of the alimentary tract.

I shall make an exploratory operation here, the clinical diagnosis being that of pseudomyxomatous peritonitis, and shall attempt to ascertain the location of the primary lesion and its character. The anesthetist has placed the patient in the Trendelenburg position. The patient is now well under the influence of ether, and I make an incision about 3 inches in length in the midline between the umbilicus and the symphysis, and, cutting down to the peritoneal cavity, I find the peritoneum pushed forward and bulging into the incision. I make a small incision into it and you see escaping from it this gelatinous material which looks like rather thick gelatin. There seems to be two different shades of color, one about the ordinary color of gelatin and one occurring in masses of more yellowish color. I extend the incision now until it is 5 or 6 inches in length, and with my two hands ladle out great masses of this gelatinous material, and filling, as you see, a basin with a gallon or more of this substance. As I do this the large omentum comes into view, and as I lift it out of the incision I find that it is attached to the wall of a large ovarian cyst which has a large rent in it, large enough for me to introduce my both hands. I now ladle out with my hands another mass, probably 2 quarts or more, of this material. I ligate the omentum from the cyst wall and then with forceps bring the cyst wall out through the incision. I find that I can do this without very much difficulty, and that there is still inside of the cyst some daughter-cysts which have not ruptured, containing the same sort of material and surrounded, as you see, with thin fibrous walls. The ovarian tumor has a narrow pedicle which springs from the left side. I bring this up into the incision, clamp the pedicle, transfix it, doubly ligate it, and then divide the pedicle and remove the cyst. There is still quite an amount of this gelatinous material in the perit-

oneal cavity and I very carefully ladle this out with my hands. One cannot wipe it off with a sponge; you can remove great masses of it with the gloved hand safer than in any other way. I examine the uterus, tube, and ovary on the right side and find they are normal except for a small fibroid about the size of an English walnut in the uterus. I examine the appendix and find nothing wrong. The coils of the small intestine that are lying in the lower portion of the abdomen are covered with implants from this process. The upper coils of the small intestine are free of the process.

This case presents an interesting problem in pathology. The disease may or may not be malignant. Many of these cases are malignant. On the other hand, some of them are benign, and after removing the primary lesion and removing this gelatinous material a few of these cases go on to complete recovery, showing that in those particular cases the process is benign and not a malignant one. These cases partake of the same characteristics that we find in papillomas of the ovary. Some of them are quite benign and some of them are very malignant. Then there are cases between these two extremes which can be cured if early removed, or which go on to a fatal termination if they are allowed to rupture and produce implantations on the peritoneum. I have followed a number of these cases and in several of them I have been rather impressed with the value of after-treatment with the  $x$ -ray. One cannot speak with absolute certainty in matters of this kind, but in several of these cases, very much like the patient we have just operated upon, we have been able to follow them for a number of years, and in several where we have given  $x$ -ray treatments there have been no recurrences. I shall, therefore, advocate the employment of  $x$ -ray treatment in moderate doses, short of any risk to the patient, as a means of after-treatment, with the hope that it will assist in destroying these implantations of epithelium on the peritoneal surface.

The second case which we have this morning is that of a man of fifty, who a year ago weighed 215 pounds. The patient



had a rather severe hemorrhage from the intestinal tract. Location of the hemorrhage was for a time uncertain, but recently with the aid of a fluoroscopic examination of the colon distended with barium from below it has been possible to make out a filling defect in the cecum. Since his first hemorrhage several months ago he has had continuously blood in the stools and has lost a good deal of weight, going down to 160 pounds. He has a tender mass in the region of the appendix and the musculature of the whole right side is rather rigid, so that it is difficult to make a very careful examination by palpation. There are two things that must be considered as probable in this case, one is carcinoma and the other is ileocecal tuberculosis. He has had at no time evidence of intestinal obstruction. On the whole, one must be inclined to a diagnosis of carcinoma because the great majority of cases of obstruction of the large intestine in men of fifty are due to carcinoma.

I shall make here a large muscle-splitting incision like an appendix incision, except I shall make it, as you see, about 8 or 9 inches in length, and after dividing the skin and superficial fascia and external oblique, I divide the internal oblique and transversalis not only up to the rectus, but split them well toward the median line, and then separate them forcibly with my hands so as to make a very large opening. On opening the peritoneum I find there is a tumor in the cecum, that it is growing into the parietal peritoneum about the cecum, and has invaded both the anterior and lateral walls. As I introduce my hand I find there is a large mass of glands extending from the primary tumor toward the midline of the abdomen in the mesentery of the cecum and of the ileum. The lesion gives one the impression of being a carcinoma. I think the case is a very serious one and the prognosis very grave because of the great probability of carcinoma, and on that account, even though the patient will run a very great risk from the operative removal, I think it will be better to give the patient the benefit of that chance. If it is carcinoma, as we believe it is, and we leave it alone, the mortality is 100 per cent. If it is carcinoma we may give him several years of comfortable life by a resec-

tion. I am deliberately doing this, though I recognize that in this particular case the operative mortality may run from 30 to 50 per cent.

I make a careful excision of the tumor including that portion of the parietal peritoneum to which it is attached. I free its base and then divide the outer layer of the mesocecum and raise up the cecum and ileum. As I do this I make a little tension upon it, and I find that I have torn into the cecum at a point where its wall has been greatly weakened by carcinomatous infiltration. I cover this up with a pad and continue my dissection so that I can remove about 5 inches of the ileum and about 6 inches of the large bowel, and a triangular wedge of mesentery attached to these two portions of the intestine and which contain some enlarged glands. I then close the ileum with a ligature after crushing it, and close the colon several inches above the ascending colon in the same way, and invaginate the ends of the intestines with two purse-string sutures of Pagenstecher linen and then make a side-to-side anastomosis between the ileum and the colon. It is evidently wiser in this case to drain than to make a complete closure of the abdominal wall. I am, therefore, introducing two moderate-sized split-rubber tubes, each one containing a wick of iodoform gauze, down through my muscle-splitting incision to the point of resection.

The operation has been prolonged and the anesthetist has very properly ordered 1000 c.c. of normal salt solution under the breast, which, as you see, has been given while I have been completing the last steps of the operation.

The after-management in this case must be one of giving the patient plenty of fluids. I shall see that he is given 1000 c.c. under the breasts every twelve hours for the first two or three days, or until he can be gotten to take a sufficient amount of fluid by the stomach. It is, of course, not desirable in a case of this kind to use fluid by rectum, at any rate no considerable amount of fluid. I think these patients should be given a moderate amount of opiates, and as soon as the patient recovers thoroughly from this prolonged ether anesthetic I shall give

had a rather severe hemorrhage from the intestinal tract. Location of the hemorrhage was for a time uncertain, but recently with the aid of a fluoroscopic examination of the colon distended with barium from below it has been possible to make out a filling defect in the cecum. Since his first hemorrhage several months ago he has had continuously blood in the stools and has lost a good deal of weight, going down to 160 pounds. He has a tender mass in the region of the appendix and the musculature of the whole right side is rather rigid, so that it is difficult to make a very careful examination by palpation. There are two things that must be considered as probable in this case, one is carcinoma and the other is ileocecal tuberculosis. He has had at no time evidence of intestinal obstruction. On the whole, one must be inclined to a diagnosis of carcinoma because the great majority of cases of obstruction of the large intestine in men of fifty are due to carcinoma.

I shall make here a large muscle-splitting incision like an appendix incision, except I shall make it, as you see, about 8 or 9 inches in length, and after dividing the skin and superficial fascia and external oblique, I divide the internal oblique and transversalis not only up to the rectus, but split them well toward the median line, and then separate them forcibly with my hands so as to make a very large opening. On opening the peritoneum I find there is a tumor in the cecum, that it is growing into the parietal peritoneum about the cecum, and has invaded both the anterior and lateral walls. As I introduce my hand I find there is a large mass of glands extending from the primary tumor toward the midline of the abdomen in the mesentery of the cecum and of the ileum. The lesion gives one the impression of being a carcinoma. I think the case is a very serious one and the prognosis very grave because of the great probability of carcinoma, and on that account, even though the patient will run a very great risk from the operative removal, I think it will be better to give the patient the benefit of that chance. If it is carcinoma, as we believe it is, and we leave it alone, the mortality is 100 per cent. If it is carcinoma we may give him several years of comfortable life by a resec-

## A GROUP OF ABDOMINAL TUMORS IN WHICH THE DIAGNOSIS IS DIFFICULT

Presentation of a Group of Abdominal Tumors in Which the Diagnosis was Obscure and in Which the Problem Arose of Determining Whether They Were in the General Peritoneal Cavity or Were Retroperitoneal. Distention of the Colon with Air a Valuable Method of Differential Diagnosis in this Type of Case. Advantages of the Muscle-splitting Incision Through the Right or Left Rectus in Ascertaining the Location of These Tumors.

THE patient upon whom I shall operate this morning is a woman of forty who has been under our observation for four or five days. She came to the hospital complaining of a large abdominal tumor. On physical examination it was not difficult to make out a very large cyst filling more than half the abdomen and located more on the left side than the right, and apparently not filling the pelvis. Her general condition is fair. She has had some pain on the left side, but no marked interference with any of the functions of the abdominal organs. On making a careful bimanual examination of the pelvis an apparently normal uterus, tubes, and ovaries were found, and no connection could be made out between the pelvic organs and this large tumor.

I studied the case with a number of my assistants, and it was interesting to ascertain their various opinions after they had examined the case. One assistant suggested that we had to deal with an ovarian cyst with a long pedicle. Another suggestion made was that the cyst might be a pancreatic cyst developing from the left side of the pancreas—the tail of the pancreas. Another suggestion made was that it was a mesenteric cyst. Another, that it was a cyst of the spleen, and finally a cyst of the kidney was suggested. On examining the patient carefully we were able to make out the fact that the cyst was

of the kidney. It is very intimately attached to the upper pole of the kidney, so intimately that I find that it requires a very fine dissection with a very sharp scalpel to dissect the cyst wall from the kidney. I forgot to tell you that the examination of Dr Herbst showed that the function of this kidney was quite normal, and therefore I do not intend to remove it. It would, of course, be a very simple thing to remove the kidney and the cyst together. As you see, it is a very tedious dissection, a rather careful dissection, to get the cyst wall cleanly away from the kidney. I have now about completed this, and just at this point as I am separating the last of the cyst wall I find I am opening into a cavity in the kidney. On close inspection and on introducing a grooved director I find I have opened the upper calix of the kidney which has been glued to the cyst wall. The cyst now is completely free, and I shall close this raw surface of the kidney with mattress-sutures of catgut, and over this a running suture of fine catgut to secure accurate approximation. I shall leave in for a few days a split-rubber tube with a little iodoform gauze wick to carry off any bleeding and primary wound secretion from this rather extensive dissection. I shall close the lumbar incision with buried catgut and two button tension sutures of silkworm-gut and the skin with black silk. The patient is in very good condition at the close of the operation.

Note.—The patient went on to an uninterrupted recovery. Examination of the cyst wall showed that it was not lined by *epithelium*, but lined by *endothelium*. If I had known this I would not have hesitated to leave that portion of the cyst wall which was in close contact with the kidney in place and simply sew the surfaces together as one might do in an aneurysmorrhaphy, an operation introduced by Matas, as endothelial surfaces of this kind will unite very rapidly if sewed together just like two layers of peritoneum.

I want to use this case as a text for the purpose of discussing with you a group of a half-dozen tumor cases which we have had in the last year in which we had to deal very much with this same problem, that is, tumors in the abdomen in which the

diagnosis was obscure and in which the problem arose of determining whether they were in the general peritoneal cavity or were retroperitoneal.

Several months ago I was called to a Chicago hospital by some medical colleagues who had had a woman under observation for several months and who had made a diagnosis of splenomegaly in a case of splenic anemia. These medical men were experts in their work and had come to this conclusion after a

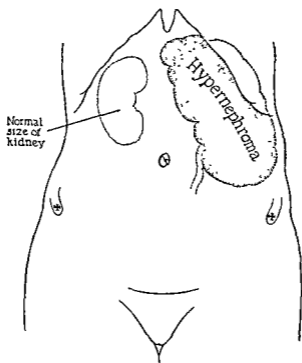


Fig. 181.—Large hypernephroma with no urinary findings and marked anemia mistaken for spleen.

very exhaustive study of the patient. I was selected to operate upon her because I had been studying and operating upon a number of these cases of splenic anemia. The patient had a very low hemoglobin, about 30 per cent., and a very large tumor on the left side filling the left upper half of the abdominal cavity and extending down to the ileum. My medical colleagues had made an examination with reference to the relation of this tumor to the colon, and had convinced themselves that

the colon was below and behind the tumor. The tumor felt like a spleen. They had satisfied themselves they could feel the notch in the spleen and that the tumor was in the general peritoneal cavity, and that it was, in fact, the spleen. I was not so convinced of this when I examined the patient because the tumor gave me somewhat the impression of a huge tumor of the kidney when I examined it. Repeated urinary examinations showed absolutely normal urine. No blood had been found at any time

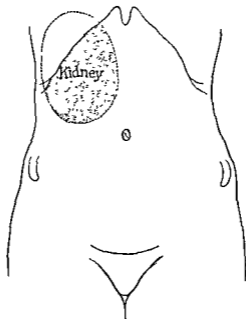


Fig 182 —Pyenephrosis of kidney in which the clinical diagnosis of greatly distended gall-bladder was made on an assurance of colleagues that urinary findings were normal.

Under ether I made our S-shaped incision through the left rectus, and on opening the peritoneal cavity I found that the tumor was in the retroperitoneal space. The spleen was quite normal and small and could be easily felt. It was rather fortunate that we made an anterior incision in this case because of the huge size of the tumor, which proved to be a hypernephroma of the left kidney. It was easier to remove it by this

transperitoneal route than by the usual oblique kidney incision. In the operation I divided the outer non-vascular layer of the descending mesocolon and separated the fold of the splenic flexure so that I could enucleate the kidney tumor, and under direct vision was able to do this without any injury to the bowel, and was, in fact, able to handle the pedicle better than I could possibly have done if I had made a posterior incision.

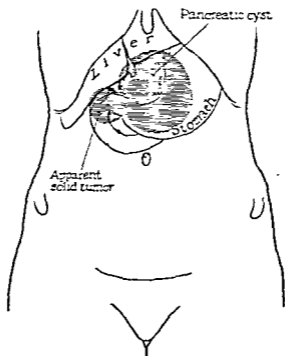


Fig. 183.—Pancreatic cyst with apparent solid tumor of pancreas.

The case, however, represented very well the difficulties met with in the particular group which we have under discussion, of determining whether the tumor is in the peritoneal cavity or in the retroperitoneal space. A few months ago one of my medical colleagues called me in to see a patient who had had a number of attacks of pain in the right upper quadrant of the abdomen. I could outline a tumor in the region of the gall-bladder. The patient was quite tender, had a little temperature, and the abdominal muscles were rigid, and after examination I had no hesitation in making the statement that we had a



distended gall-bladder to deal with. I did this, too, on the basis of the information given me that the urinary findings were perfectly normal and that there had been no evidence of pus or blood in the urine. The next morning I proceeded to operate upon the patient, with the understanding that we were dealing with a gall-bladder. I did not in this case inflate the colon with air, which I should have done. I opened the peritoneal cavity

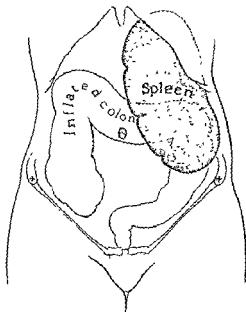


Fig. 184 —Large spleen in case of splenic anemia which had first been explored, with the diagnosis of kidney lesion

through an S-shaped incision through the right rectus and came down to a perfectly normal gall-bladder, but a tumor situated in the retroperitoneal space and in connection with the right kidney. I closed the anterior incision at once completely and made an oblique kidney incision, and came down upon a hydronephrotic kidney with a very greatly distended pelvis and calices and containing urine and pus. The kidney itself was so greatly thinned that it was evident from the macroscopic appearance that it

was of no value to the patient, so I proceeded to do at once a nephrectomy. The patient went on to a complete recovery.

Shortly after this my colleague, Dr. Bertram W. Sippy, referred to me a very interesting cyst which occupied the middle of the abdomen, developing in the midline between the ensiform cartilage and the umbilicus. The cyst apparently was the size of a large grape-fruit. In addition to the cyst, which could be quite well outlined, was a smaller noncystic mass extending to the right and occupying apparently the position of the right kidney. I had several expert surgeons examine the case, and their general conclusion was that it was a retroperitoneal tumor and that it was connected with the right kidney. Dr. Sippy, after examining the case carefully, was quite fixed in his own mind that we had to deal with a pancreatic cyst. I was rather inclined to the same opinion, and yet evidently the case was not at all clear. I operated on the patient in the clinic given to the surgeons attending the Clinical Congress of North America, and Dr. Sippy presented the case fully with his diagnosis and the reasons for making the diagnosis of pancreatic cyst. In that case I made a median incision between the ensiform and the umbilicus, and on opening the peritoneal cavity I found that we had a large retroperitoneal cyst to deal with. It occupied the median line and it came almost to the surface between the liver and the lesser curvature of the stomach. With a good deal of difficulty, on account of the large number of blood-vessels which were lying in front of the cyst wall, I finally freed the cyst wall after dividing the gastrohepatic omentum and ligating a large number of blood-vessels, and opened the cyst containing about a quart of fluid, evidently and clearly a pancreatic cyst. The smaller mass lying to the right side of the cyst seemed to me a solid mass in connection with the head of the pancreas, and I did not venture to attempt the removal of this mass. The woman is still under observation, and a small drainage-tube is still in the cyst cavity which secretes a small amount of fluid and a little pus. The general condition of the woman is improving. I have not as yet been able to determine the exact character of the growth attached to the head of the

pancreas It may be another smaller pancreatic cyst developing in the head of the pancreas or it may be a neoplasm springing from the pancreatic tissue

Another case which we had recently which comes into this same group was one in which even after exploratory operation an accurate diagnosis was not made The patient was a woman of forty who had rather suddenly developed a tumor in the right upper quadrant of the abdomen We had here again the problem as to whether we had a tumor of the gall-bladder or a tumor of the kidney to deal with, and we were not able after a careful study of the kidney and after inflating the colon to make a differential diagnosis My general impression was that it was a malignant growth developing from the gall-bladder I therefore made an anterior incision and came down upon a normal gall-bladder and upon a large mass, the size of a good-sized orange, surrounded by adhesions involving the omentum and intestines. In palpating the mass, however, I at that time satisfied myself that we had to deal with a tumor of the right kidney, probably a hypernephroma, and I made that diagnosis after the exploratory I felt, however, from the condition that the case was inoperable and made no attempt to remove the right kidney The woman died about six or seven weeks after the exploratory, and the postmortem examination showed that we had neither a tumor of the kidney nor a tumor of the gall-bladder to deal with, but a lymphosarcoma of the small bowel which had produced no obstruction in any way, but which had led to a plastering of all the structures in the right upper quadrant together, forming a plastic malignant peritonitis which made it impossible to make a differential diagnosis at the time of the exploratory

Another case which proved to be of particular interest was that of a patient upon whom I operated a few weeks ago. We had an opportunity of studying this case at the Presbyterian Hospital for a number of months A young woman, the wife of a physician, had a large tumor mass in the left side of the abdomen She was seen by one of my colleagues in internal medicine, who called into consultation one of our col-

leagues in urology. After a careful laboratory study of the case they came to the conclusion that it was a kidney, and finally did an exploratory operation, exposing the kidney by an oblique kidney incision, and found the kidney perfectly normal and that the tumor was the spleen. She recovered from the exploratory and shortly after became pregnant, and at the time of confinement had a very severe hemorrhage which necessitated a number of transfusions, her hemoglobin going down to about 20. She finally went on to a recovery. Later I saw her in consultation with Dr. Wilbur Post and Dr. Phemister, and we came to the clinical diagnosis of a splenic anemia. We had her under general management and tried arsenic and some x-ray treatments. Her general condition improved. She then became pregnant the second time, and it was thought wise to bring on an early miscarriage, which was done. After another consultation I came to the conclusion that it was much safer to do a splenectomy than to leave the patient alone, as it was almost certain to develop into a Banti's later, with cirrhosis of the liver and perisplenitis. I therefore did a splenectomy. At operation I found rather extensive adhesions from the perisplenitis, but no evidence of cirrhosis of the liver. She went on to a good recovery. This case is rather startling because it is a case which was handled by quite competent men, and in which a differentiation between a spleen and a kidney mass was not determined definitely until an exploration of the kidney was made.

Another case which we have had within the last few weeks presented this same problem of differentiation between a retroperitoneal tumor and one inside the peritoneal cavity. A woman of fifty had a mass in the right upper abdomen about the size of a grape-fruit, which could be felt between the palpating hands; one hand in the right kidney region and one on the anterior surface of the abdomen gave one the sensation of a large kidney or a large tumor in connection with the gall-bladder or the liver. She had some pus in the urine, and on that account a pyelogram was made, which showed a normal kidney pelvis on the right side. Distention of the colon with gas showed that the colon was below this mass and that the mass was, therefore, almost

certainly intraperitoneal. I made a muscle-splitting incision over the right rectus and found a huge malignant tumor of the gall-bladder. The process had already invaded the liver, the round ligament, and the omentum, and was inoperable.

Within the last year we have had 3 cases of abdominal actinomycosis with masses on the right side of the abdomen, in the flank, and in the anterior portion of the abdomen. In all 3 of these cases we made an oblique kidney incision entering the retroperitoneal space and opening into retroperitoneal actinomycotic abscesses. In one of them in addition to this we had to open an abscess in the appendix region, and in the third there was a swelling under the liver which disappeared under iodid, copper, and x-ray treatments.

We have here the same problem as to whether the lesion was intraperitoneal or retroperitoneal. Of course, in these cases the primary lesion was intraperitoneal, but extended as these cases usually do to the retroperitoneal space, where it is easier to open the abscesses and drain them and avoid opening into the general peritoneal cavity.

In presenting these cases I do so for the special purpose of calling your attention to a method of differential diagnosis which has been in late years too much neglected, and that is the simple inflation of the large intestine with air from the rectum. *This can be readily done either with the ordinary Davidson syringe or with a rubber bag distended with air and a tube introduced a few inches into the rectum and the air gradually allowed to enter the bowel.* The patient should be placed flat upon the table, and before the air is introduced the outline of the abdominal viscera should be carefully determined both by palpation and by percussion. Then as the air is introduced one should especially determine the question as to whether the colon as it distends occupies a position in front of the tumor mass or whether it occupies a position below the mass toward the symphysis. Since the introduction of the x-ray this simple means of differential diagnosis has not been very generally employed, and we have trusted altogether too much to the x-ray findings in these cases. These are not nearly as valuable as the evidence

furnished by inflating the bowel. It may be in a few cases, but, as a rule, inflation of the bowel with air gives us much more definite evidence of the intra- or retroperitoneal position of the mass than a fluoroscopic with barium in the bowel or plates with barium in the bowel. As I have analyzed this group of cases I am satisfied that most of the mistakes could have been prevented if this simple old-time and well-tried-out method had been employed. It certainly would have made unnecessary a number of the cystoscopic examinations and pyelograms. I want to, therefore, particularly emphasize this point and urge the general employment of dilatation of the colon in these cases. It is true that in some emergencies and in some atypical cases it may be either impossible to employ this simple test, or it may not furnish us determining evidence, and in these cases we may have to resort to an exploratory in order to definitely locate the site of the lesion.

If it is necessary to make an exploratory to determine whether the tumor is in the peritoneal cavity or in the retroperitoneal space, I prefer to make the small muscle-splitting incision either through the right or left rectus, as this will give us the opportunity, if necessary, to make a complete exploration of all the abdominal contents, and if at this exploratory it is found that the lesion is retroperitoneal and that it cannot be attacked except through an oblique kidney incision, we can then close the anterior incision and complete the operation through a posterior cut. There are, however, a group of cases, such as kidney tumors, in which we may very satisfactorily enlarge the anterior incision and employ it to expose and remove the tumor.



# CLINIC OF DR. ALBERT J. OCHSNER

AUGUSTANA HOSPITAL

---

## THE TREATMENT OF CASES SUFFERING FROM CANCER WITH THE ACTUAL CAUTERY

Case I. Carcinoma of the Chest Wall—History, Operation,  
Microscopic Report.

Case II. Tumor of Left Frontal Sinus—History, Treat-  
ment.

Case III. Carcinoma of Mouth—History, Operation.

Conclusions Arrived At as the Result of Studying These 3  
Cases.

Case I.—Mrs. A., No. 78,349, age fifty-eight, occupation  
housewife, was admitted January 15, 1924.

Patient first noticed the beginning of the tumor three years  
ago. She came for treatment to Augustana Hospital the first  
time in September, 1923. At that time she had a hard im-  
movable tumor attached to the anterior chest wall extending  
from the upper edge of the mammary gland to the clavicle  
above and to the right edge of the sternum. *x*-Ray and radium  
were applied under the direction of Dr. Henry Schmitz. The  
tumor was so adherent and had advanced so much of late that  
its removal seemed out of the question, but there seemed some  
chance of benefit from preliminary radiologic treatment.

After the radium treatment the mobility of the tumor  
against the chest wall has improved greatly, so that its removal  
now seems indicated. The induration surrounding the tumor  
proper has disappeared so that the growth is quite circum-  
scribed over an area 12 cm. in diameter. The general condition  
of the patient has not changed. The heart shows an enlarge-  
ment of 1½ cm. outside the nipple line; sounds clear; no mur-  
murs. Pulse is regular and strong. There is no edema. The  
lungs show no peculiarity.



Diagnosis: Carcinoma of the upper chest wall.

*Operation.*—The patient was given a hypodermic injection of  $\frac{1}{4}$  grain of morphin and  $1/150$  gr of atropin one and a quarter hours before beginning the anesthetic and  $1/6$  gr. morphin and  $1/200$  gr. atropin one-half hour before the anesthetic. She was then anesthetized thoroughly with ether, with the table in the horizontal position. Then the ether was removed and the head of the table elevated to 45 degrees in order to cause an anemia of the brain

The face was then covered with a towel saturated with water in order to prevent an explosion of the exhaled ether. A number of ordinary small-sized soldering irons are placed in a blue gas flame, such as are in use by tinsmiths. These irons are heated to red heat, and with them the skin is cut entirely around the tumor, which is cut away together with a rim of apparently healthy skin 3 cm in width. The entire operation is performed with the red-hot iron. The entire bed from which the tumor has been removed is then cooked with the hot iron quite down to the ribs and the sternum.

It seems important to keep the hot iron in contact at each point sufficiently long to have the terrific heat penetrate beyond the depth of tissue actually destroyed. In case one simply passes the hot iron back and forth instead of leaving it in contact longer at each point, the heat does not have an opportunity to penetrate the deeper tissues.

Undoubtedly a portion of each of several ribs will be exfoliated and a portion of the sternum and possibly the clavicle, but this is of no importance. Cauterization is carried on until one feels certain that all the malignant tissue has been actually destroyed or cooked. In this location one must be careful not to burn a hole into the chest cavity through the intercostal muscles and pleura between the ribs, because this can be done very easily with the red-hot edge of the soldering iron. When one has apparently destroyed all of the carcinoma and enough tissue beyond to feel satisfied that no malignant tissue is left, the wound is dressed by the application of a sheet of sterile mosquito netting, which has been filled with hard melted paraf-

fin, and this is covered with an ordinary dry aseptic dressing. All cut vessels which may bleed during the operation are caught with hemostatic forceps, and the latter are heated by touching them with the cautery iron, which will seal them so that ligatures are usually not necessary. It is remarkable how little these patients suffer from pain following these extensive operations with the cautery irons.

After the eschar has separated we will cover the surface with Thiersch skin-grafts, then we will inspect the surface at first every month, and later less frequently. If any recurrent nodule appears, this is destroyed at once with the cautery.

We have a number of patients well today, some of them over twenty years, who were apparently in as hopeless a condition when they came under our care as the present patient. In some of these quite a number of recurrent nodules had to be burnt away from time to time. The important point is to destroy these nodules the moment they appear, and always to destroy them thoroughly. This can be done under local anesthesia with  $\frac{1}{2}$  per cent. of novocain.

The microscopic section of the present tumor shows it to be a typical breast cancer. Evidently this has originated from a lobule of the upper inner border of the left breast. The cells show the characteristic changes due to the effects of exposure to x-ray and radium.

Case II.—Mr. G. A. W., No. 77,761, age fifty-six years, occupation butcher, was admitted December 13, 1923.

On October 25, 1923 his physician first saw this patient. He then had a small tumor in the region of the left frontal sinus. Thirty years ago he had suffered from a blow to this region. Headaches started three months ago.

On November 19th the left frontal sinus was opened and a grayish mass occupying the frontal sinus and extending into the anterior ethmoidal cells was removed. This proved to be a periosteal sarcoma. The bone underneath and behind the tumor was partly destroyed. The tumor was adherent to the meninges.

Twenty-four hours after the operation 100 mg of radium was placed in the interior of the cavity for twenty-four hours. Ten days later he had deep x-ray therapy applied over the entire left frontal region including the eye, but it does not seem likely that the disease has been entirely eradicated.

We have consequently decided to make a radical removal of what may be left of the growth, together with a sufficient portion of the surrounding tissues to make a permanent cure probable.

The orbital plate of the frontal bone is involved. In similar cases we have made the observation that whenever we have tried to save the eye, we have lost our patient from recurrence. We will, consequently, cut away with the cautery iron the eye, together with all of the contents of the orbit, including the orbital plate of the frontal bone, and the tissues surrounding the original growth. This makes quite a gruesome operation, but it gives the patient a fair chance for a permanent recovery. All surfaces are carefully exposed to the tremendous heat of these cauteries. The cavity is then tamponed with gauze and an aseptic bandage applied.

Later, when the surface becomes covered with granulations, the entire area is covered with Thiersch skin-grafts. In this patient we are quite as careful to keep the red-hot iron in contact with every portion of the surface, and to burn into the bone as in the previous case. It will require a month or longer for the destroyed bone to loosen. In some instances we have cut away with chisel or bone forceps the portion of the bone that has been destroyed by the heat in order to facilitate the healing.

This can be done without fear of carrying any cancer infection into the healthy tissues, because our destruction has been so extensive that we can be sure that all malignant tissue surrounding the tumor proper has been destroyed, but in order to be sure that no further bone will become necrotic one will have to cut away more bone than will be sacrificed if one waits for the sequestrum to separate.

We have made the mistake of leaving the eye in similar cases

in the hope of saving this organ in a number of cases only to experience an inoperable recurrence and the loss of the patient's life. It is for this reason that I wish to direct attention especially to the importance of sacrificing the eye at the time of the first operation.

Case III.—Mr. Charles T., No. 77,715, age fifty-five, occupation traveling salesman, was admitted November 23, 1923.

For about four years patient had a fissure at the left angle of the mouth which was painless, but slowly increased in depth. This was cauterized twice in 1921, at six-month intervals, with electric cautery in March and August. In 1922 he noticed an extension to the inside of the mouth, which was diagnosed as leukoplakia by one physician and epithelioma by another.

During February and March, 1923 he had x-ray and radium applied. October 12, 1923 he had a large quantity of radium applied, which made him feel very ill for a week. On November 3d he noticed a swelling on the outside of the cheek, bluish red in color. This has increased in size during the past three weeks. It is now 3 cm. in diameter opposite the left angle of the mouth directly opposite an ulcerated surface on the inside of half the diameter.

Evidently the patient is suffering from what started as a fissure upon which an epithelioma has developed which yielded at first somewhat to treatment with radium and x-ray, but which seems to have been stimulated to more rapid growth by the application of radium six weeks ago.

We have repeatedly made the observation that cases of epithelioma that are not entirely cured by the first treatment of radium or x-ray may be greatly stimulated in their growth by a subsequent treatment. This is not, however, a general rule, but it does happen in some cases, and whenever it does happen we have found that we have had the best results if we have at once removed the entire growth far into the healthy tissues whenever this was possible because of the location of the tumor. When this has not been possible, the patient has usually succumbed to the advances of the tumor. We will,

consequently, remove this growth very extensively with the actual cautery and will do the best we can in correcting the deformity later. The microscopic examination proved the tumor to be an epithelioma. The fact that the prognosis is vastly more favorable in cases in which malignant growths have been removed with the actual cautery than in similar cases in which the operation has been performed with the knife has been stated so often by so many surgeons with great experience that it should have been generally accepted long ago.

It is, however, usually only after a surgeon has tried the method in a case which he and other experienced surgeons have considered absolutely hopeless in which the cautery was applied experimentally and was followed by a permanent cure that the surgeon will begin to use the actual cautery systematically in all advanced cases of malignant growths. In our clinic the method has been in use now for a period of thirty-six years, and we have a large number of patients alive who were treated by this method, some from every year during this entire period. I am convinced that among those who are alive today a large percentage would have died from recurrence or metastases had the malignant growths been removed with the knife instead of the cautery.

Our experience seems to justify the following conclusions:

1. Whenever there is any doubt about the ability of making a complete removal of a malignant growth with the knife, this should be done with the actual cautery.

2. The cautery should be applied in many cases that are apparently hopelessly advanced, because this group contains a considerable number which will remain permanently well after removal with the actual cautery.

3. The effect of the tremendous heat radiating from the cautery iron seems to extend a considerable distance beyond the tissues that are actually destroyed.

4. The ordinary small-sized soldering iron makes an exceedingly satisfactory instrument for use in this operation.

5. It seems best to keep the cautery in contact continuously at each point for a sufficient time to get the effect of the heat at

a considerable depth rather than by simply passing the cautery back and forth quickly, which will simply destroy the tissues coming actually in contact.

6. The method can be applied with equal advantage to sarcoma and carcinoma.

7. There is remarkably little shock and almost no pain following the operation, even in cases in which large areas have been burned, as for instance, carcinoma of the breast.

8. It seems wise to give carefully planned x-ray treatment preliminary to the removal of malignant growths with the cautery.



# CLINIC OF DR. THOMAS J. WATKINS

ST. LUKE'S HOSPITAL

---

## HIGH RECTOCELE

### Technic Employed in the Treatment of High Rectocele

*History in Abstract.*—Mrs. K. is sixty-six years old; weight 127 pounds; menopause at fifty. Received relief for a number of years by wearing pessary.

*Symptoms.*—Chiefly mechanical disturbances from protruding rectocele.

*Findings.*—Rectocele, cystocele, and small enterocele. Uterus is senile, in about normal location and position.

*Illustrations.*—The illustrations are accurately drawn from life by Tom Jones, except Fig. 185, B, which is diagrammatic. Figures 185 and 188 are from the case of Mrs. K., the others were drawn from another patient, and are used here for the purpose of facilitating and visualizing the description.

In Fig. 185, B the perineal body is displaced backward and is not torn. The rectovaginal fascia was torn across the upper part of the vagina and has retracted into the perineum, except laterally, where it has remained more or less attached, as shown in Fig. 188. The cystocele is kept from protruding by the large rectocele. The enterocele may have been slightly deeper, but was not large, as will be noted later.

*Etiology.*—The rectocele is probably due chiefly to the perineal body being displaced downward below the pubes by pressure of the child's head during labor. This puts the rectovaginal fascia on longitudinal tension, and such tension always means a *transverse* tear. The tear is most likely to occur at the *upper part* of the vagina where the fascia is weakest.

*Extent of the Lesion.*—Rectocele, like other hernias, probably starts, as a rule, from a small lesion and becomes larger as the result of stretching and retraction of the tissues.



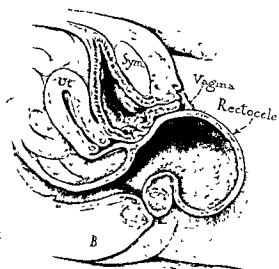
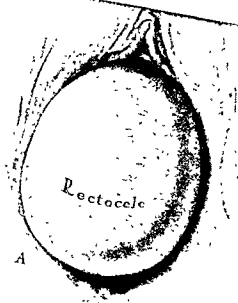


Fig 185—A B

*Hernial Repair*—The vaginal mucosa is separated from the rectum along the median line the entire length of the rectocele

by means of blunt dissection with scissors, leaving the mucous membrane flap as thin as possible. This is accomplished by scissors, as shown in Fig. 186. Repeated short longitudinal incisions and blunt dissections are made for the purpose of sacrificing a minimum amount of tissue. This leaves a narrow mucous membrane flap on either side which are grasped with 8-inch forceps, and the mucous membrane is then "skinned off"

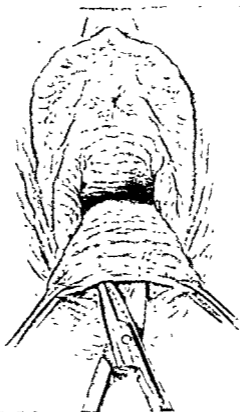


Fig 186 —Blunt dissection of vaginal wall over rectocele.

from the rectocele extending well beyond the hernial sac. In Fig. 187 the finger is used to demonstrate the hernial ring. Figure 188 shows the mucous membrane flaps retracted and the fascial flap held up. The upper border of the torn edge of the fascia (which was retracted and which was originally located in the upper part of the vaginal canal) is readily sutured to the base of the broad ligaments on either side without appreciable

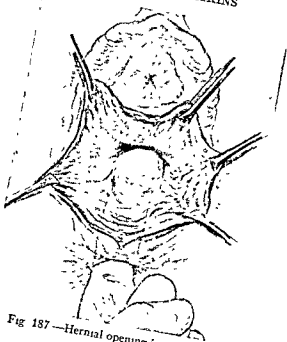


Fig 187—Hernial opening in rectocele

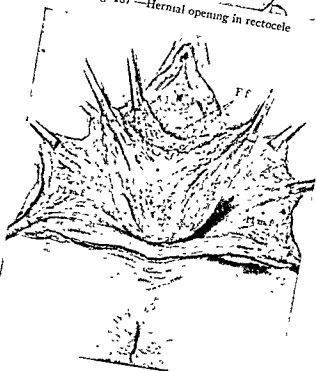


Fig 188

tension. Experience in thorough dissections of high rectocele induces me to believe that there is always sufficient firm tissue in cases of rectocele for closure without undue tension.

Figure 189 shows the sutures passed through the base of the broad ligaments on either side, picking up the free edge of the rectovaginal fascia.

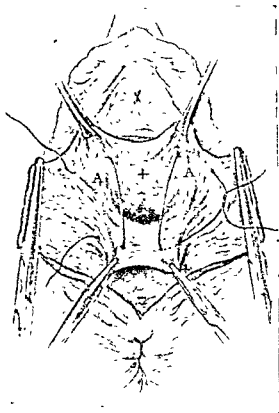


Fig 189.—Torn edges of fascia; flaps are sutured to the broad ligament and posterior to the cervix.

The method of suture in high rectocele varies in individual cases. I intended opening the peritoneal cavity behind the cervix, excising the enterocele, and suturing to the uterosacral ligaments. On dissection, however, the pouch was found very small, and, consequently, the method of suture shown in Fig. 189 was utilized.

In closing the hernial opening it is always necessary to ob-

serve care not to constrict the upper part of the vaginal canal. This makes it inadvisable to close the opening by a circular suture. Additional interrupted sutures are used to insure complete and firm closure.

Figure 190 shows the hernial wound closed. The rest of the wound is sutured in the ordinary way.

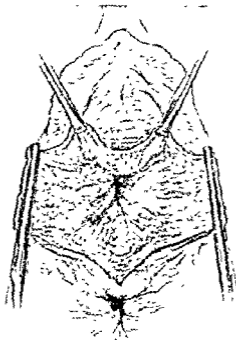


Fig. 190—Hernial opening closed (Drawn from life)

*Remarks*—The subjective symptoms in such cases are surprisingly slight considering the extent of the lesion. This is probably due to the fact that the hernia is a gradual growth and that the muscle in the rectal wall increases by compensatory hypertrophy.

Thorough dissection of high rectocele always shows an abundance of firm tissue for closure. The percentage of failures should be less than in ventral or inguinal hernias because of the

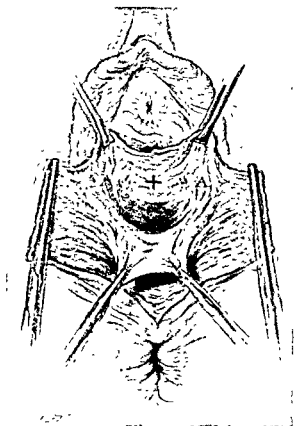


Fig. 191.—Indicates location of cervix: *A*, Broad ligament on either side.  
Torn edges of fascia retracted by forceps Rectal hernia.

constant presence of a large amount of strong retrovaginal fascia which can be utilized in the closure.



## CLINIC OF DR. DANIEL N. EISENDRATH

MICHAEL REESE HOSPITAL

---

### CONGENITAL STRICTURES OF THE URETER

Types of Congenital Affections of the Ureter. Description of Each. Presentation of 2 Cases Illustrative of Congenital Stricture of the Ureter.

THE subject of ureteral strictures is perhaps the most actively debated one in the field of urinary surgery. We have begun to appreciate what an important part they play not only in giving rise to changes in the kidney but also in causing reflex symptoms referable to the bladder. Ureteral strictures may be either congenital or acquired. That the latter may develop upon the former cannot be denied. Some urologists believe that all strictures develop as primary postnatal conditions, but this view does not explain our findings in embryos and children. I am of the opinion that a certain proportion of ureteral strictures are truly congenital in origin, arising as the result of defective development. The 2 patients who are presented today are examples, I believe, of the group of congenital strictures, and resemble in many respects the 4 cases which I have previously published.

Before discussing the latter and today's cases in detail permit me to direct your attention to congenital affections of the ureter in general. These may be classified as follows:

1. Strictures.
2. Twists.
3. Valves.
4. Diverticula.
5. Dilatations without obstruction in the ureter, bladder, or urethra.



1. **Strictures.**—These are in all probability due to imperfect canalization of the solid epithelial outgrowth from the wolffian duct, which represents the ureter in the embryo. By the fourth month, when the first urine passes through the ureter, canalization should be complete. It is not difficult to visualize the

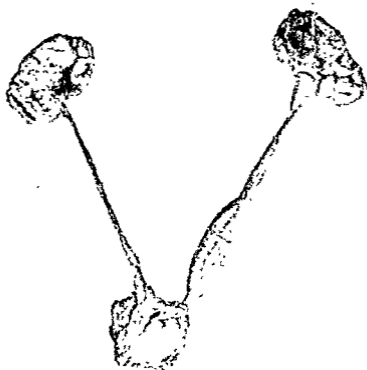


Fig. 192.—Autopsy specimen from ten-day-old infant obtained through the courtesy of Dr. I. A. Abt. There is a marked narrowing of the ureter in its juxtavesical portion and again just below the renal pelvis. Note the marked dilatation of left ureter between these two strictures.

effect of a failure of one or more segments to be canalized. In this manner a narrowing or complete absence of the lumen can be readily understood. Even in the normal human ureter there are certain points or levels at which the lumen is distinctly less in diameter than elsewhere. These points are: (a) in the segment immediately adjacent to the renal pelvis (b), where the

ureter crosses the iliac vessels, and (c) in the juxtavesical portion, *i. e.*, just before the ureter enters the wall of the bladder. The first and third of these points of narrowing are the most constant. The lumen of the ureter between these two is invariably wider, so that one may find one or two so-called "spindles," the former (Fig. 192) if there are only two narrowings, and the latter (two spindles—a lumbar and a pelvic) if there is a third or intermediate point of narrowing where the ureter crosses the iliac vessels.

Strictures of congenital origin are found after birth in one of the following locations or combinations:

(a) Close to the renal pelvis or to the bladder on one side of the body, *i. e.*, at the levels where narrowings of the normal ureter occur most constantly. My second, third, and fourth cases (B, C, and D respectively of Fig. 193) belong in this group.

(b) At one of the levels referred to in (a), but on both sides of the body. All possible combinations have been reported, *e. g.* at the vesical end of the ureter on one side and the upper end on the other side, or vice versa.

(c) Bilateral stricture at or about the same level. These are most common at or close to the vesical end of the ureter, often giving rise to a condition known as cystic dilatation of the ureter, which will be more fully described later. In my first case (A of Fig. 193) there was a cystic dilatation on the left side and a stricture of the juxtavesical portion of the opposite ureter. In addition, there was a twist in the upper ureter of the left side.

(d) Stricture at the vesical end of one or both of the ureters of a double kidney usually with a blind ending and protrusion at the normal location of the ureteral orifice or elsewhere in the bladder, usually close to the internal meatus. This is well illustrated in one of Tilp's cases. (See Fig. 194.)

2. **Twists or Torsion of the Ureter.**—This condition most frequently occurs in the middle and upper thirds of the ureter. It is present in many normal persons to a slight degree, but only gives rise to clinical symptoms when, as in my first case (see A

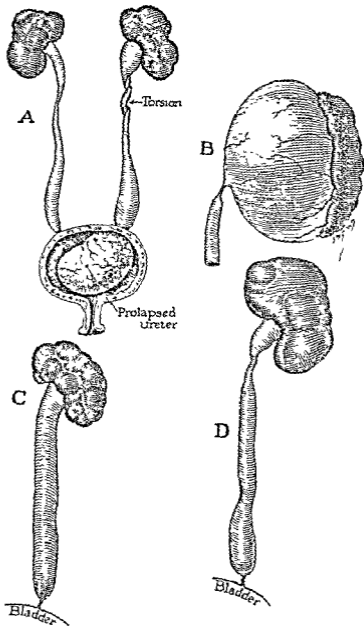


Fig 193.—Four previously published cases of the author: A, Cystic dilatation of lower end of left ureter with torsion of lumbar portion of same ureter. Stenosis of juxtavesical ureter on opposite side (Girl of seven) B, Stenosis of ureter close to kidney with resultant enormous hydronephrosis (Boy of twelve) C, Stenosis close to bladder, with resultant dilatation of ureter and renal pelvis (Boy of fourteen) D, Stenosis at same location as in Case C, but impermeable, with much greater dilatation of ureter and renal pelvis

of Fig. 193), the torsion is so marked as to result in a more or less complete occlusion of the lumen.

3. Valves.—These are found in about 20 per cent. of all individuals and occur at any level. Like a torsion, they seldom if ever give rise to any obstruction, because in order to do so the free edges must have remained united so as to form a diaphragm. Such valves were seen in my second case (B of Fig. 193), but were not the cause of the ureteral dilatation.

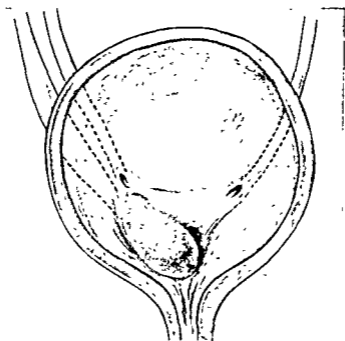


Fig. 194.—Appearance of opened bladder showing cystic dilatation of lower end of the ureter of the lower half of a double kidney. Note minute ureteral orifice close to internal meatus (Tilp).

4. Diverticula.—These may occur either singly or multiple (Fig. 195). They may play an important rôle clinically if the seat of an infection or point of lodgment of a calculus. There are comparatively few reported cases of either variety which have been recognized clinically.

5. Dilatation.—I do not refer to those dilatations which have been reported secondary to valve formation in the urethra or to a stricture of the vesical end of the ureter. English was

one of the first to direct our attention to so-called idiopathic dilatations, and a number of such cases (Fig. 196) are being reported in recent articles. With the introduction of ureteropyelography we have been able to recognize a relatively large number. Their importance from a clinical standpoint cannot be underestimated. The subject of congenital dilatation of the ureter has developed so rapidly that I can only mention it, as it seems advisable to limit ourselves to a discussion of congenital

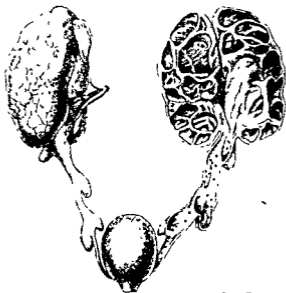

Fig. 195—Multiple congenital diverticulæ of both ureters complicated by bilateral hydronephrosis (Peperè)

ureteral strictures and their sequelæ as illustrated by my previous cases and those shown today.

*Previously Published Cases.*—My first case was one of cystic dilatation (A of Fig. 193) of the lower end of the left ureter in a girl of sixteen. It presented itself under the clinical picture of urinary retention complicated by infection of the corresponding kidney. The intravesical protrusion was treated by open operation, a method which has been superseded by the high-fre-

quency current, as we shall see later. There was a complicating twist of the ureter which was not recognized until nephrectomy became necessary on account of the persistence of the renal infection. Death occurred five months later of uremia. A stricture of the opposite ureter was found close to the bladder.

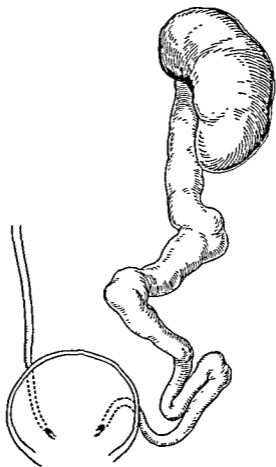


Fig 196 —Drawing of autopsy specimen from case of congenital dilatation of the ureter without stricture (Maresch)

In a second case the presence of a huge abdominal tumor attracted the attention of the physician who referred the twelve-year-old boy. A diagnosis of kidney tumor was made, but at operation we found an enormous hydronephrosis due to a stricture at the ureteropelvic junction (B of Fig. 193).

In the third and fourth cases the strictures were in the

juxtavesical portion (C and D of Fig 193) of the ureter. In both cases the symptoms of renal infection predominated. In one there was a history of an acute onset, apparently the first attack. This was in a fourteen-year-old boy. In the other case, a man of twenty-eight, there was a history since the age of fourteen of recurrent attacks of colicky abdominal pain accompanied by fever and the presence of an abdominal enlargement which had gradually become a prominent feature of the case.

In the cases which I present today the one was a woman of twenty and the other a girl of seven.

Case I (Case V of My Series).—Patient was referred for urologic study by Dr. C. E. Kahlke, to whom she had been sent with a diagnosis of gall-stones. There was a history of a sudden onset four months before, of a chill followed by high fever and severe pain in the right upper quadrant of the abdomen. This attack was the first of a series with a similar clinical picture which recurred every seven to ten days and was accompanied by pyuria.

On palpation an enlarged and tender right kidney was found. The bladder, aside from a moderate degree of trigonal cystitis, revealed nothing abnormal. The urine from the right catheter contained a number of pus-cells in each field. There was an obstruction in the right ureter about 15 cm. from the ureteral orifice. No phthalein was excreted on the right side in thirty-five minutes, while on the left side it appeared in five minutes. A ureteropyelogram (Fig 197) revealed a stricture of the right ureter, which began opposite the third lumbar transverse process and ended in a kidney which showed the typical pyelographic appearance of complete destruction, namely, a series of round shadows due to the filling of greatly dilated calices by the contrast fluid (sodium iodid 12.5 per cent.).

Upon removal of the kidney I found the conditions shown in Figs 197, 198. In the former illustration you will observe the stricture in the uppermost portion of the ureter, ending in a bifid renal pelvis. The markedly lobulated surface is familiar to you

as indicative of extensive destruction of the parenchyma. This was confirmed by section of the kidney, which revealed the fact (Fig. 198) that scarcely a particle of renal tissue remained, *i. e.*, an advanced hydronephrosis.



Fig 197.—Pyelogram (slightly retouched) from Case 1 of congenital stricture of the ureter in its lumbar portion with resultant hydronephrosis. Compare with Figs. 198, 199.

Here we have a history similar to that obtained in 2 of the 4 previously published cases, *i. e.*, perfect health until adolescence. Then the clinical picture of an acute renal infection either with



a single or recurrent attacks. Let us see if this girl of seven, the second of today, presents similar features.

For the past four years, *i. e.*, ever since the age of three, there is a history of recurrent attacks of pain over the left kidney region. At times the severity of the pain required the administration of opiates. During the preceding two years she

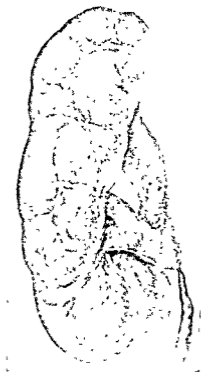


Fig. 198 —Outer aspect of kidney in Case I, showing hydronephrosis. Note bifid character of renal pelvis, also note strictured portion of ureter.

had been attended by Dr. Eugene O'Neill, who referred the patient, adding the information that there was tenderness over the left kidney for several days after an attack.

I made a diagnosis of pyelitis, and upon urologic study found a moderately reddened trigone of the bladder. The left ureteral orifice gaped, was quite prominent, and one could see

flocculi of pus escape at intervals. I would have been content with the diagnosis of pyelitis had it not been for the ureteropyelogram (Fig. 200). This revealed an abrupt conical lower termination of a much dilated left ureter. Although I was able to pass a No. 5 catheter on this side, the stricture must have been quite narrow to have resulted in such a degree of dilatation

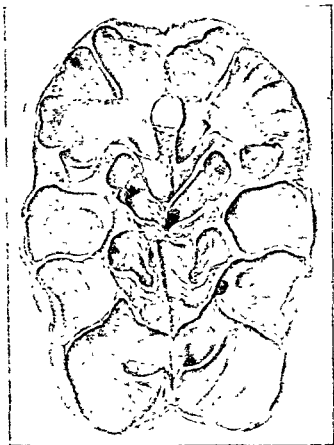

Fig. 199—Sectional view of kidney in Case I, showing advanced hydronephrosis.

of the ureter and renal pelvis. The capacity of the latter was 20 c.c. I have dilated the left orifice up to the size of a No. 8 F. ureteral bougie and followed it with a lavage of 1:500 nitrate of silver solution. There has been no recurrence of attacks for eight months, an interval which far exceeded any other for the past two years. The dilatation with ureteral bougie will be con-

tinued at intervals, and it will be of great interest to make a later ureteropyelogram. I feel confident that we are dealing




Fig 200.—Pyelogram (slightly retouched) from Case II of congenital stricture of the ureter at its vesical end. Note abrupt ending of ureter at its lower end and dilatation from this point upward, including renal pelvis.

here with a congenital stricture of the vesical orifice of the ureter with resultant proximal dilatation of the ureter and renal pelvis.

Study of the pyeloides of children with the aid of ureteropyelography is warmly urged in order to avoid overlooking a

possible congenital stricture as the factor which favors the persistence of the infection.

In closing the clinic I will recall to your mind a few of the essential features of congenital strictures, with special reference to one of the important sequelæ, viz., cystic dilatation of the vesical end of the ureter.

1. Congenital strictures occur most frequently close to the kidney or to the bladder.

2. These may be found in various combinations:

(a) At both ends of the same ureter.

(b) At the vesical end of one side and the upper end of the other, or vice versa.

(c) On both sides at the same side.

3. They may be complicated by dilatation of the ureter and renal pelvis according to the degree of stenosis. The latter is seldom complete.

4. The clinical pictures do not differ from those of ureteral stricture of acquired origin, viz.,

(a) Pain the predominant symptom.

(b) Fever and other signs of renal infection.

(c) Abdominal tumor.

(d) Intravesical protrusion of the lower end of the ureter (cystic dilatation).

5. With the exception of the last-named sequel the treatment does not differ from that of ureteral strictures of acquired origin.

A few words in conclusion regarding cystic dilatation. This is the result of a more or less complete congenital occlusion of the vesical orifice of the ureter with resultant protrusion into the bladder lumen of all of the structures composing the wall of the ureter. It may or may not, like congenital stricture in general, be complicated by calculous formation. The tumor varies greatly in size according to whether or not there is a minute opening for the escape of urine at the apex of the protrusion. The typical appearance at autopsy is well shown in Fig. 201, from one of Boström's cases. The tumor may prevent the escape of urine from the opposite ureteral orifice, with resultant

obstruction of that side. Again, it may completely fill the lumen of the bladder so as to give rise, as in one of my cases (A of Fig 193), to urinary retention. An unusual complication of cystic dilatation is seen in Fig. 202, viz., the prolapse (in the female) of the tumor through the external meatus. A number of such cases have been reported. The diagnosis of cystic dilatation in general depends upon the cystoscopic examination

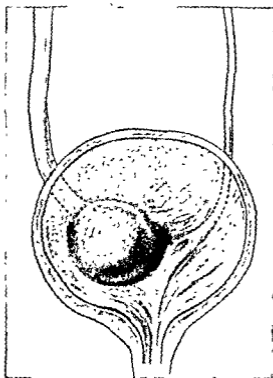


Fig. 201 --Appearance of open bladder in a case of cystic dilatation of the lower end of the right ureter (Boström)

One observes a protrusion (Fig. 203) at the corresponding ureteral orifice which greatly resembles a case of phimosis. The minute opening at the apex is very difficult to find at times. The differentiation from other conditions, such as prolapse of the lower end of the ureter complicating a calculus or edema of

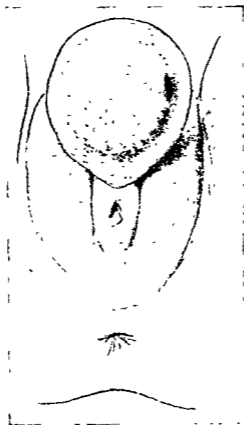


Fig. 202.—Appearance of vulva in a case of prolapse through the urethra of a cystic dilatation of the ureter (Geipel and Wollenberg).

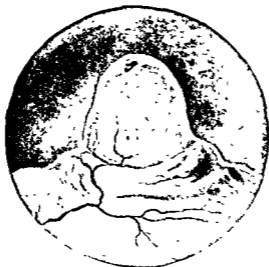

Fig. 203.—Cystoscopic appearance of cystic dilatation of lower end of ureter (Baetzner).

the lips of the orifice, is not very difficult. Over 100 of these cases of cystic dilatation have been collected to date.

The ideal treatment at the present time is to open the protrusion with the aid of the high-frequency current. Open surgical procedures are contraindicated and unnecessary.

## CLINIC OF DR. KELLOGG SPEED

### FRANKLIN HOSPITAL

#### TRAUMATIC LESIONS OF THE HEAD OF THE RADIUS. RELATION TO ELBOW-JOINT DYSFUNCTION

Anatomy of the Elbow-joint. Classification of Lesions of the Head of the Radius. Treatment.

It is intended to discuss principally the pathology of these lesions embracing pure fracture of the head of the radius, which occurs in adults, fractures of the neck and head, which occur mainly in adolescents, dislocation of the head of the radius with fracture of one or both forearm bones, and the subluxations of the radial head seen in small infants, the so-called "pulled elbow." A distinct differentiation between fractures of the head and neck of the bone as occurring in the young is difficult because of the narrow anatomic area involved and because the two lesions often coexist. The lower limit of all these fractures is formed by the bicipital tuberosity; any lesions below this point must be classed as fractures of the radial diaphysis.

Turning our attention to the anatomy of the elbow-joint, we find that the radial head at the superior radio-ulnar joint articulates with the radial notch in the ulna, forming a trochoid or pivot joint. Here practically all of the bony motion of pronation and supination of the forearm occurs. The radial head also so fits that in flexion and extension of the forearm it does not impinge against the external condyle of the humerus to interfere with a full range of elbow-joint motion. That joint motion is governed by other factors. The excursion of the coronoid process of the ulna into the coronoid fossa of the humerus, aided by the stretching limit of the capsular ligament and the triceps tendon and the mass of soft parts in front of the joint



limit flexion of the forearm, usually to an angle not less than 30 to 35 degrees with the arm. Extension of the forearm is limited

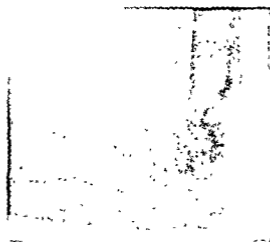


Fig. 204.—Lateral view of the elbow in the case of J. S. The comminution of the radial head is now clearly shown, together with splitting down into the neck, a typical picture of the bone pathology in adolescents. In the posterior recess of the joint are shown several smaller fragments, possibly from fracture of the external condyle of the humerus, but probably from the head of the radius. The epiphysis of the olecranon has also been disturbed.

by the arrested excursion of the olecranon into the olecranon fossa of the humerus, aided by the tenseness of the capsular



Fig. 205.—Skiagram of removed head after recent fracture in an adult, Mrs. B.

ligament, the pull of the biceps tendon in front and the muscle bellies crossing from arm to forearm.

The superior radio-ulnar joint is bound around by the an-

nular ligament which forms four-fifths of the osseofibrous ring holding the radial head to the ulna. This ligament blends below with the anterior and posterior capsular ligaments of the elbow-joint, but is reasonably loose to allow the joint rotatory motion in its lower part. Its inner surface is smooth, lined with synovia, and is continuous with the elbow-joint proper. Consequently, dislocations and fractures involving the radial head must effect some dysfunction in the use of the elbow-joint. This interference may involve pronation and supination only, or, in addition, may limit flexion and extension of the forearm, much depending on the character of the lesion and the pathology produced

Study of the pathology may be simplified by making some classification of the various lesions. Let us adopt this as a working model:

I. Fracture of the head of the radius:

(a) Complete:

- (1) Partial or marginal, fragment dislocated out of position.
- (2) Total, as comminutions or crushings, with deformity of the head.

(b) Incomplete, usually fissures extending to the neck, with the two fragments remaining in some contact.

Associated lesions:

Fracture of the upper end of the ulna, coronoid, or olecranon, common.

Fracture of the lower end of humerus, uncommon.

Dislocation of the radius, usually forward and outward.

Dislocation of both forearm bones, complete or incomplete, backward or divergent.

II. Fracture of the neck of the radius, mostly in children eight to eleven years.

(a) Incomplete, fissures in various directions, infraction.

(b) Complete, transverse or oblique, generally about 1 cm. below the articular surface, decapitation, sometimes the separation is epiphyseal.

## Associated lesions:

Fracture of the external condyle of the humerus.

Fracture of the olecranon or coronoid.

Fracture of the epitrochlea

Dislocation of elbow backward.

Dislocation of radius forward.

III. Fracture of the diaphysis of the ulna complicated by dislocation of the upper end of the radius, most cases in those four to five years of age

IV. Subluxation of the head of the radius in infants—"pulled elbow."



Fig. 206.—A recent fracture of the ulnar shaft accompanied by decapitation of the radius. These two lesions frequently are associated and the injury of the radial head is overlooked. Inexplicable dysfunction in the elbow-joint results after the ulna has healed, and later operation for removal of the displaced head will promise considerable increase of elbow motion.

Fracture of the head of the radius is six or seven times as frequent in men as in women. The condition has been des-

cribed by Malgaigne, an instance was shown before the Anatomical Society of Paris in 1851, and in 1860 Bruns collected 22 cases. These fractures are frequently total crushings or comminutions of the bone head, so that the cancellous bone beneath the cartilaginous covering may be crushed and splintered while the cartilaginous surface remains intact. Usually, however, the



Fig. 207—Anteroposterior view of a case of some years' standing in which there had been a fracture of the head of the radius and the ulnar shaft. A surgeon had devoted his attention to the nailing of the ulnar fracture, neglecting the more important head of the radius, which had united in malposition and with much new bone formation, locking the elbow-joint and inhibiting pronation and supination.

head as a whole is compressed, so that its normal contour is lost, its diameter is increased, bony spicules project, and mechanical interference with rotatory motion follows whenever the distorted head attempts to turn against the ulna or meets resistance from the annular ligament. I have seen one instance in which the cartilaginous cover was ripped off the bone and

lay within the elbow-joint. When the fracture is comminuted there may be decapitation of the bone with multiple divisions of the fractured head. The annular ligament may be torn,



Fig 208 --Lateral view of the elbow in the case of J B two months after resection of the head of the radius. Both ulna and radius are healed. The amount of new bone growth about the head of the radius interferes with forearm flexion

pieces of cartilage-covered bone fragments may be expelled through the capsular ligament out into the periarticular tissues by the fracture violence or by forced elbow movements. Frag-



Fig 209 --Experimental fracture of the external humeral condyle in a dog by arthrotomy. The defect from which the fragment was chiseled is seen at A. This surface after one week was healing over with connective tissue, while the displaced bone fragment left loose in the joint was found at a distance grown firmly adherent to the synovia at its area of contact.

ments of bone may come to lie freely in the elbow-joint, ultimately to be forced into its recesses, especially up on to the humerus in front or out into a lateral pocket of the joint.

Hemarthrosis is generally present; its absorption is delayed, the synovial fluid is very thick, and may be tinged by blood-pigment for weeks. When this condition has persisted a long time detached bone fragments may become attached to underlying bone or cartilage, which we have seen in man and found also experimentally in dogs. New bone formation may result from the injured root of the head of the radius or from any bony neighboring area which was subjected to irritation. The



Fig. 210—Anteroposterior skiagraph of a comminuted fracture in a youth (J S). The radial head is flattened and distorted, and one fragment, partly cartilaginous, is seen at *A*. The epiphysal line seems unseparated. Although there may be some fracture of the humeral condyles it is not definitely shown in this view.

displaced bony fragment, the vitality of which is probably maintained by synovial fluid present, may proliferate. Capsular changes are usually those of shrinking, thickening, and involvement in bony complications and attachments. Any one of the three main nerves at the elbow may be involved primarily or secondarily.

Partial or marginal fractures are the most frequent. The split off fragment of bone covered with cartilage is displaced in

any direction, usually forward, and is often seen lying toward the external condyle of the humerus. It may become a freely moving body in the elbow-joint, getting in the way of the articular surfaces to cause pain and restricted motion. Rarely the fragment is on the posterior surface or is displaced backward.

When any of the associated lesions given above are present the pathology is further complicated and a discussion of them would require much time. The symptoms are first those of the



Fig 211 —Final operative correction in the case of J B. The ulnar deformity has been partly overcome, the head of the radius shortened, and adventitious bone removed. Over the head, to prevent further new bone formation, a cap of transplanted fascia has been sutured. Under massage and directed motion function in the elbow rapidly increased and now approaches 85 per cent normal.

attitude of the patient common to most elbow-joint injuries. The forearm is held by the opposite hand, usually in a position of about 90 degrees flexion. Swelling is fairly rapid, free fluid or blood in the joint may be determined. Ecchymoses appear within two days. Palpation of the radial head finds a point of exquisite tenderness, and when the fracture is complete crepitus may be felt. The functional interference of the elbow is not at first given much notice. The patient may be able to flex and extend the forearm two-thirds of a normal extent with little

pain. Complete extension causes pain. Active pronation and supination, especially the latter, are greatly restricted, and passive attempts to produce them cause severe pain.

Incomplete fractures of the radius head are usually fissures involving only part of the head, generally the anterior half. They extend toward or into the neck, and the two fragments may separate at the joint surface, but remain in contact lower down like a V. One fragment may be subdivided by other fissures. Extra-articular displacement of bone is rare in this type, but the changes in the size, shape, and smoothness of the radial head inhibit complete active rotation of the radial head



Fig. 212.—Specimen of removed head of the radius in the case of A. T. The adherence of capsular tissue and new bone formation can be seen.

by impingement and blocking or pain. If the condition is unrecognized the irritation of the loosened bone is continued by movements, the capsule and synovia tend to adhere, and a fibrous or even an osseous reaction is set up in the elbow-joint capsule. All these factors which induce pain on motion lead to constantly increasing reduction of elbow movements. Early rest and immobilization, on the other hand, may cause nearly a full functional return if the head is not deformed sufficiently to block rotation. Fragments of the head tend to unite; the action of the synovial fluid is not inimical to bony union as far as our experiments show.



Fracture of the neck of the radius, which occurs mostly in children, is really an artificial subdivision of head fractures, as the head is so often involved both by the planes of fracture and the displacement of fragments.

The incomplete lesions are fissures in various directions, sometimes resembling greenstick fractures or infraction, displacement is usually angular, head outward and upward. These fractures are inclined to heal quickly and give a minimum amount of dysfunction, supination alone being somewhat restricted.

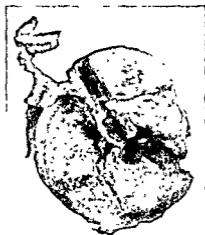


Fig 213 —Photograph of the specimen of the head of the radius removed in the case of J P C This is an average case occurring in male adults with promise of great dysfunction in the elbow-joint if the head is not removed early

The complete fractures are either transverse or oblique, with the plane of fracture about 1 cm. below the articular surface. Decapitation may be found, but the fragment is usually thicker on the external border. The dentate character of the fracture plane and the ligaments tend to hold the fragments in apposition with the head tilted. The associated lesions mentioned may be present. These injuries without displacement tend to mend in fifteen to twenty days, and there is relatively little interference with motion at the elbow. When the fragments under-

go greater displacement corresponding limitation of motion results, supination suffers mostly. Cubitus valgus may result.

Fractures of the diaphysis of the ulna complicated by dislocation of the upper end of the radius are lesions seen in adolescents. Practically all fractures of the ulna except the tip of the olecranon and the styloid process may be thus complicated. Fractures of the lower part of the ulna are not so frequently concerned, because the two bones are more superficial at that



Fig. 214—Anteroposterior view of a fracture of the head of the radius of two years' standing in an adult man (W. R.). Note again the tendency for new bone formation on all sides of the joint.

level, and fracture of both is most liable to result from direct violence. In the upper part of the ulna dislocation of the radius may accompany as high as 80 per cent. of the cases. The accident is four times as common in males as in females. The brachialis muscle pulls the ulna forward and the interosseous ligament holds it to the radius, so that in fractures at the base of the olecranon both bones usually hold together and are dislocated forward. Tags of torn capsular ligament may closely embrace the head and neck to form insuperable obstacles to reduction.

The complications found are:

Open fracture, head of radius sticks out of soft parts.

Associated fractures:

Ulna, or epiphyseal separation of the lower end of the radius.

Both forearm bones, middle or lower.

Head or neck of radius

Nerve lesions:

Primary radial paralysis

Vascular lesions, rare.




Fig 215 —Removed head of the radius in the case of H. C. The smallest fragment lay high up in the elbow-joint in front of the humerus

The prognosis after complete early reduction is good. If the

head cannot be reduced there may result

Vicious union or pseudarthrosis of the ulna.

Cross-union between the two bones.

Deformity

Muscular atrophy

Loss of pronation and supination

Loss of all but few degrees of flexion and extension.

If the dislocation persists the radial head atrophies (rarely hypertrophies), flexion of the forearm is greatly diminished. In a child the upper end of the radius may overgrow until the bicipital tuberosity comes to lie at the joint level, and osteo-




Fig. 216—Anteroposterior and lateral views of a comminuted fracture of the head of the radius (three weeks old) in an adult woman (Mrs F. A. S.). At *A* is seen a large fragment displaced into the joint.



Fig. 217.—Anteroposterior view of the case of H. C. This appears to be a marginal fracture, but on closer inspection the whole head seems fractured off, with a loose piece lying at *A*.

phytes may be produced from torn periosteum folded back over the radial head. If sufficiently abundant, ankylosis of the elbow follows. The forearm may take on a valgus position with change in relation of ulna and radial styloids and changes in position of the carpal bones. The functional disturbances in the elbow are usually loss of flexion beyond 90 degrees in adults (not so in children), incomplete extension of the forearm, and loss of pro-



Fig 218—Skiaogram of experimental fracture of the head of the radius produced in dogs by open operation. In each instance a clean wound resulted and bony union was quite well advanced one month later, when the specimens were obtained. Gross examination revealed defect along the cartilaginous surfaces which was rapidly healing and which caused no intra-articular adhesions. A and B, Microscopic study revealed normal callous formation, and it was apparent that the synovial fluid had not interfered with bony union. One dog had been allowed to walk on his leg for three weeks, beginning one week after the operative fracture, but the result of the bone healing was not interfered with.

nation and supination. In older dislocations the torn annular and capsular ligaments become adherent to the head of the radius, hanging over it like a fibrous apron. Even if the head could be returned to normal position its articular surface is thus ruined and full motion could not be expected to return.

Subluxation of the head of the radius or "pulled elbow" occurs in infants just learning to walk. A person lifting the child

by one arm over an obstacle or up a stairway may give a jerk on the hyperextended hand and pull the forearm so that the capsular and annular ligaments are torn, to permit the radial head to be dislocated forward to a slight degree. There is loss of function and some deformity of the misplaced radial head, often unnoticed for some time, although the child may cry, fail to use the hand, and object to passive movements. Attempts at re-



Fig. 219.—Operative repair of the case of I. V. The surgeon nailed the olecranon and in so doing split it further. The fractured radial head remained unremedied.

duction by pressure on the head and a retention in a light splint in acute flexion will lead to complete functional recovery. If the head remains out of position, the carrying angle remains permanently changed, but all elbow-joint motions are normal, hyperextension usually being possible.

The treatment of these injuries may be briefly summarized. Practically all lesions of the head of the radius in adults except fissure fractures and fractures with no displacement require re-

removal of the head of the bone. That alone promises a maximum functional return, especially of pronation and supination. Old fractures with exostoses, adherence to the joint capsule, restricted motion, pain, interference with nerves and loss of power certainly indicate resection up to several years after the injury.

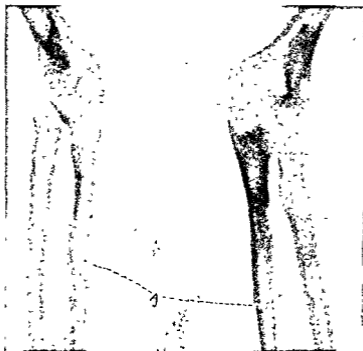


Fig 220 —Anteroposterior and lateral views of fracture of the shaft of the ulna (A) and of the neck of the radius in a young boy (M S) The epiphysis of the external condyle of the humerus has been tilted out of position

In children with growing bones and in infants resection is not indicated. One must not interfere with the epiphysis for fear of growth deformity, and the loss of function is naturally overcome in great degree. Exceptions lie in ankylosed joints or those in which there is tendency to much new bone formation. After head resection in such children or even adults we use a modified arthroplasty by means of transplanted fascia.

CLINIC OF DRS. ALFRED A. STRAUSS, JOSEPH  
FRIEDMAN, AND LEON BLOCH

MICHAEL REESE HOSPITAL

---

COLECTOMY FOR ULCERATIVE COLITIS

Presentation of 2 Patients in Whom this Operation was Performed Some Weeks Ago. Operation—Technic. Pathology and Etiology of Ulcerative Colitis.

AFTER we have presented to you this morning 2 very interesting cases of ulcerative colitis in which operation was performed several weeks ago, we will perform an operation for ulcerative colitis on a third patient.

CASE I

The first patient, aged forty-three, was operated on twice before, first in April, 1922, when appendicostomy was performed. She weighed 87 pounds at that time, the hemoglobin was 35 and the red count 1,600,000, and she was practically moribund. Before operation the patient was given two blood transfusions and 1 quart of 5 per cent. glucose intravenously every day for two weeks until her general condition permitted an appendicostomy under local anesthesia. A gridiron incision was used. The appendix was ten times the normal size, with typical thickening and infiltration of the various muscle coats and slight ulceration at the point of amputation, and the cecum and entire colon were infiltrated. A few days subsequent to operation the patient was given a third blood transfusion, and daily for one week 1 quart of 5 per cent. glucose was given intravenously. When slowly she had gained in weight and strength, we irrigated through the appendicostomy morning and evening with large quantities of normal salt solution.



The patient returned seven months later, having gained about 35 pounds, but the hemoglobin remained at 40 and the red count 1,650,000; and she still had diarrhea with more or less bloody stools containing mucus, undigested food, and some pus. We felt at that time that she had made as much progress as was possible with an appendicostomy, and therefore decided on ileostomy.

This case, and a similar one in which we performed ileostomy after appendicostomy, demonstrate the inefficiency of appendicostomy for the treatment of severe ulcerative colitis. This case illustrates also that simple irrigation through an appendicostomy is not sufficient; for the shutting off of the intestinal content from the diseased bowel is the greatest factor in alleviating the severe symptoms of ulcerative colitis. This can be done only by ileostomy. Flushing of the pus and sediment and keeping the mucosa of the colon washed clean through an appendicostomy are of certain aid, but absolute rest for the colon and the prevention of contractions, peristalsis, and irritation are of more importance.

**Ileostomy.**—The appendicostomy, which was done through a gridiron incision, was loosened, the appendix amputated and the stump inverted, and the ileum sutured in the form of a knuckle and brought through the same opening. It is ideal to perform these ileostomies through a gridiron incision. At the time of ileostomy the cecum and ascending colon, as far as the latter could be seen, were in better condition than at the time of appendicostomy. The thickness of the bowel wall was practically normal; it was not as much infiltrated and had a more healthy color than seven months previously. The sigmoid, however, was still hard and markedly infiltrated, but the ascending colon had healed somewhat. One advantage of ileostomy over appendicostomy is that the patient can be on a full mixed diet without irritating the inflamed colon. It is surprising how readily these patients gain in weight and strength after ileostomy.

Three months after ileostomy the patient returned with an acute arthritis of the right knee and ankle, which improved

under ordinary medical management. During the next year she had recurrent attacks of arthritis, affecting the shoulders, knees, and ankles, confining her to bed or her home the greater part of the time. Also, in spite of constant irrigation, blood and pus were discharged from the rectum, and the patient evidently was suffering from a mild form of chronic sepsis with periodic chills and fever. We therefore decided on colectomy to remove the source of infection.

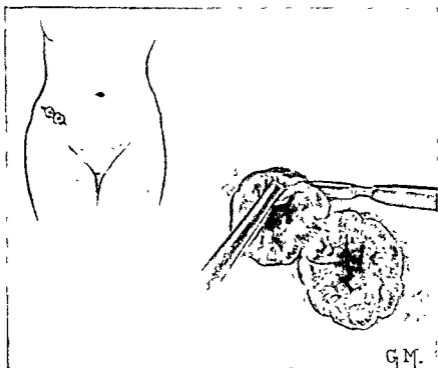


Fig 221 —Freeing the ends of the ileum from the skin.

**Colectomy.**—The proximal and distal ends of the ileum at the ileostomy were freed from the skin and divided completely, and each end closed and inverted with a purse-string suture (Figs. 221, 222). The area was then sealed up with cotton and collodion so as not to contaminate the rest of the abdomen. A midline incision was made from the pubis to the umbilicus, extending slightly upward into the left rectus muscle for 4 cm. The short distal end of the ileum was dissected out of the ab-

dominal wall, and the cecum and ascending colon freed from the parietal peritoneal attachment and the colon amputated, the mesentery being caught in clamps as the dissection proceeded (Fig 223). The greater omentum was carefully freed

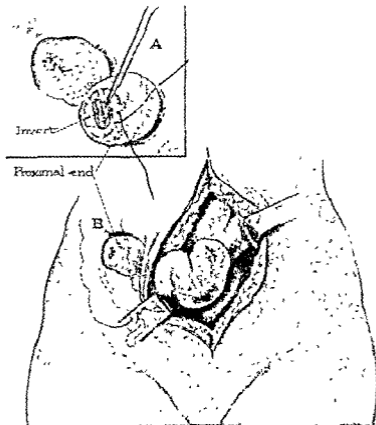


Fig 222—*A*, Sewing the purse-string suture around the distal end of the ileum and inverting the stump, *B*, removing the distal end of ileum from the deostomy opening, leaving the proximal end in place

from the transverse colon, which was then cut away from its mesenteric attachment. The splenic flexure, descending colon, and sigmoid were removed in the same manner up to the upper portion of the rectum, which was doubly clamped and divided with cautery. All of the mesenteric vessels were carefully li-

gated to insure absolute hemostasis. The rest of the rectum was closed and inverted with a purse-string and brought out through a small stab wound in the left lower quadrant. The midline incision was closed except for a small amount of drainage in the various layers of the abdominal wall (Fig 224) A drain was inserted also in the small opening in the abdominal

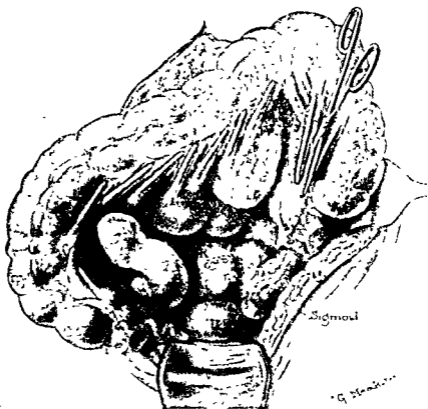


Fig. 223 —Removal of colon, the mesentery being divided between clamps.

wall caused by removal of the distal end of the ileum at the site of ileostomy. A blood transfusion of 500 c.c. of blood by the direct Luer syringe method<sup>1</sup> completed the operation.

For a few days after operation the patient had a moderate reaction, with rapid pulse, more or less regurgitation, and watery

<sup>1</sup> Clinic of Dr. Alfred A. Strauss, Surg. Clin. of North America, 3, 1033, August, 1923.

diarrhea. The upper abdomen was markedly distended, owing to chronic atonic dilatation of the stomach. We noticed in all of our colectomies that at the end of the operation, as we were closing the abdomen, the stomach became large and atonic. This is probably caused reflexly by the cutting away of a large area of bowel from its mesentery. At the end of two weeks the patient developed a left parotitis, which cleared up within a

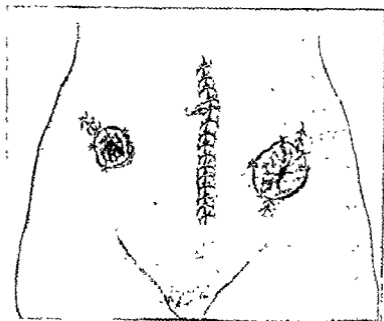


Fig 224 —Midline incision closed The end of the ileum is at the site of the ileostomy, in the right lower quadrant, and the upper end of the remaining portion of the rectum is brought through a stab wound in the left lower quadrant

week without suppuration. She has gained steadily until the present time, and is now, as you can see, practically ready to leave the hospital. Four days after operation the patient stated that all joint pains had ceased, and it was evident on examination that the swelling of the knee- and ankle-joints had disappeared. The patient has gained about 25 pounds since colectomy was performed and has markedly improved.

**Pathology.**—As you can readily see from this specimen (Fig. 225) and from the roentgenogram taken before operation, the wall of the colon is thickened and the lumen narrowed; and as one can readily see from the roentgenogram, the colon has contracted to about two-thirds of its normal length, practically obliterating the hepatic, splenic, and sigmoid flexures. The mesentery that has been left attached to the colon contains many infiltrated lymph

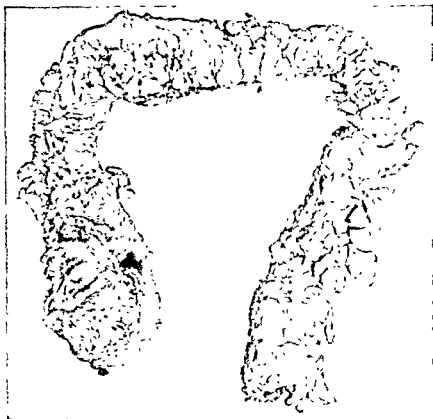

Fig 225 —The shortened and thickened colon removed in Case I.

glands, which vary from the size of a pea to that of an almond. The cecum and ascending colon are markedly thickened and dilated, having the appearance of a large thickened pus-bag, which on opening contains a great deal of pus. The wall of this portion of the bowel is at least five times its normal thickness. The mucous surface (Fig. 226) is raw, reddened and granular, and very little mucosa is left. The wall of the transverse colon is

not quite as thick as that of the cecum and ascending colon and is more contracted, and the lumen is narrower. The descending loop and sigmoid, the latter practically a straight tube, are also markedly thickened, the inner surface being very similar to that of the cecum and ascending colon.

Microscopically sections from various parts of the colon present practically a uniform picture in that in places there are

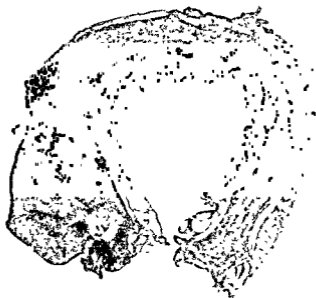

Fig 226—Opened colon of Case I showing markedly dilated cecum and ascending colon, thickly infiltrated walls, narrowed transverse and descending portions, and obliteration of the hepatic, splenic, and sigmoid flexures

small papillary projections which contain mucosa. The epithelium contains many goblet-cells, and the stroma is rich in lymphocytes and plasma-cells, and contains a few polymorphs. In several areas the mucosa is completely replaced by subacutely and chronically inflamed granulation tissue. The muscular layers are very thick and contain many lymphocytes, plasma-cells, and occasional leukocytes. The pericolonic fat also contains a few of the same inflammatory cells. In some areas the inflammatory exu-

date replacing the mucosa is particularly rich in plasma-cells. There is no evidence of malignancy.

#### CASE II

The second patient, also a woman aged forty-three, seven years ago had a period of diarrhea with bleeding and one rather extensive hemorrhage. Six months after the onset an appendicostomy was performed through which the colon was subsequently irrigated; but the hemorrhages recurred and an ileostomy was performed in November, 1916. Six months before the present admission the patient noticed that blood and mucus were again passing from the rectum, at first every two or three days, becoming more frequent, until on admission it was a daily occurrence. These hemorrhages were accompanied by marked loss of weight and strength, so that on admission the patient weighed about 95 pounds and was hardly able to walk. Physical examination revealed no abnormality except for proctoscopy, which disclosed a narrowing in the rectum about 7.5 cm. above the anus, with polypoid growths which on histologic examination proved to be carcinomatous. On attempting to irrigate the colon, a catheter passed only 15 cm. beyond the ileostomy opening and only 1 ounce of fluid could be injected. It was evident from the attempted roentgenography and irrigation that the ascending colon was completely strictured near the cecum. The hemoglobin was 80, red count 4,300,000; the stools were liquid, containing mucus and blood. In view of the report of malignancy in the rectum, the patient's rapid loss of strength and weight, the abdominal discomfort, and the strictured colon, complete colectomy with removal of the rectum was decided on.

The same technic as in the previous case was followed, with the addition that, on account of a large fibroid of the body of the uterus and an interligamentous fibroid of the uterus, it was necessary to perform hysterectomy in order to remove the rectum. After hysterectomy the mesorectum was freed, and the rectum detached from the levator and internal sphincter muscles from above. The upper rectum was doubly clamped and divided with cautery. A purse-string suture was used on the



lower end, which, with a rubber catheter (Fig. 227) was everted and pulled through the anus and completely cut away (Fig. 228). The abdomen was closed, but the abdominal wound was drained in layers on account of the postoperative infection which usually occurs in the abdominal wall.

The patient subsequent to operation appeared to be in shock, and an immediate transfusion of 600 c. c. of blood was given, the patient leaving the operating-room with a pulse of

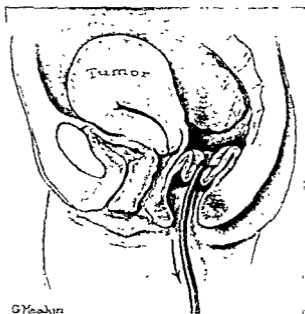


Fig 227—Rubber catheter sutured to upper end of rectum, which is being everted and pulled through anus

80 and apparently in excellent condition. Twelve hours after operation the pulse again became very rapid and the patient was pale, there was a question of diagnosis between secondary shock and hemorrhage. We decided it was shock and treated it as such, giving 3 quarts of physiologic salt solution and some epinephrin subcutaneously, and instantly the pulse decreased to below 100. The removal of the uterus, the rectum, and the entire colon from its mesentery had produced tre-

mendous dehydration of the body plus a certain amount of shock from the two-and-a-half-hour operation, but the patient made a quick recovery. Two days later there developed in the abdominal wall an infection with a gas-forming organism, from which also the patient recovered.

As in the first case, atony of the stomach followed removal of the colon. At the end of forty-eight hours the patient, though taking a large amount of fluid, was having slight regurgitation; there was marked upper abdominal distention with a flaccid abdomen. This atony, however, disappeared in about five days.

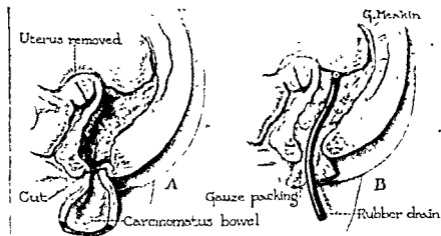


Fig. 228.—A, Everted rectum being cut away from anal margin; B, gauze pack and rubber tube in rectal fossa.

The patient had also a diarrhea which persisted for about ten days regardless of medication to produce constipation and to prevent hyperperistalsis. The patient for thirty-five days seemed in fairly good condition, the wound healed, the bowels were moving, but suddenly there developed acute pain in the left chest and lumbar region, foul breath, and attacks of paroxysmal cough. The temperature gradually became higher and, although lung abscess was suspected, the Roentgen ray at first revealed very little, but in one week revealed a definite localized area in the left upper lobe anteriorly. Later, in the third left interspace 5 cm. from the left sternal border, there was a slight

bulging, which was cut down on. An abscess was found in the lung, *slightly lateral to the left auricle*. The abscess drained profusely and the temperature went down. The patient was more comfortable, and the prognosis now is excellent. She has practically recovered from the abdominal condition

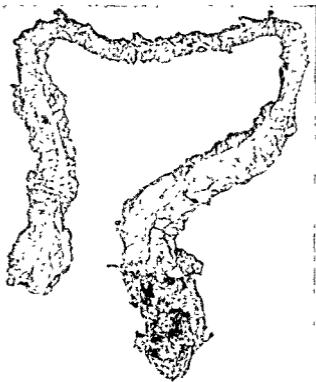


Fig 229—Colon removed in Case II, showing the marked narrowing of the transverse colon and dilatation of the cecum, ascending and sigmoid portions

**Pathology.**—As you will note from the specimen removed at operation (Fig 229), there is marked thickening and dilatation of the cecum and of about 7 cm of the ascending colon. From there on, the colon is contracted to about the size of the little finger, with complete obliteration of the lumen. At the lower end of the sigmoid the bowel is again dilated; when removed

it contained a great deal of pus. The wall at this portion is much more infiltrated, and the inner surface (Fig. 230) looks reddish and granular, with very little mucosa left. The entire rectum, which is carcinomatous, shows many polypoid growths, hard and infiltrating, having the feeling of carcinoma on gross

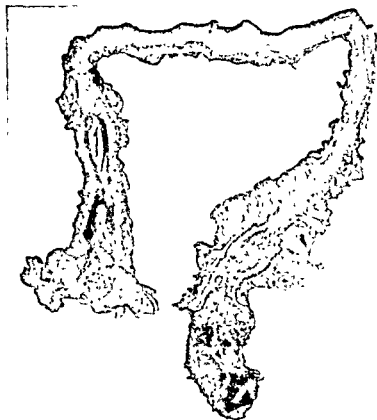


Fig. 230—Opened colon in Case II, showing obliterated lumen of descending and transverse colon, and dilated cecum and ascending colon, with markedly thickened wall.

examination. The entire colon is contracted to two-thirds of the normal length, as it was in the previous case.

Microscopically the mucosa is completely missing except for one raised ragged area in the distal 10 cm. of the bowel. The area is firm and one section is infiltrated. There is much fibrous tissue in the wall of the bowel, especially in the cecal region and in the first 5 cm. of the ascending colon, but the hepatic flexure,

transverse colon, and descending colon are atrophic and obliterated. Microscopic sections taken through the rectum and sigmoid reveal an apparently unrestrained glandular overgrowth which is embedded in a mass of subacutely inflamed granulation tissue. There is great variation in the size of the cells and in the chromatin content of the nuclei composing the overgrowths. There are many mitotic figures. The mucosa is completely replaced by granulation tissue containing granular neoplasm. The muscular layers are diffusely infiltrated with polymorphs, many eosinophils, and many lymphocytes. In several areas the tumor definitely invades the muscular layers. Sections of the upper portions of the colon show the mucosa to be entirely replaced by subacutely inflamed granulation tissue. The muscular layers also are rich in eosinophils and lymphocytes, and the serosa has many lymphocytes on its outer surface. Sections through the ileum show an exudate in the lumen which is rich in mucus, blood and pus, red blood-cells, and polymorphs. The various layers of the ileum are free from inflammatory or neoplastic processes.

### CASE III

The man on whom we are to operate this morning is thirty-two years of age and gives a history of medical treatment for three years for periodic attacks of diarrhea, which at times became so severe that he was confined to bed for weeks. The stools, for the most part, were watery and contained mucus and, occasionally, much blood. The patient was very anemic, having lost much blood during a long period, the hemoglobin was 20, and the red count 1,300,000. He came into the hospital one year ago in almost moribund condition. His temperature ranged from 100° to 103° F and the pulse from 100 to 130. He had at that time, or prior to admission, what was assumed to be a pleurisy, but, in reality, was probably an embolic affair in the lungs which gave the symptoms of pleurisy with effusion. At the same time a typical phlebitis developed from an embolus in the femoral vein. Both of these conditions demonstrate that infectious emboli may be

thrown into the circulation in extreme cases of ulcerative colitis.

In December, 1922 we performed an ileostomy following blood transfusion, and the patient has improved markedly since then, at present weighing 157 pounds, with 80 per cent. hemoglobin and a red cell count of 5,000,000.

However, while the patient looks healthy, he has more or less discomfort on account of toxic absorption from the infected colon, and blood and pus in the stools have been frequent in the last few months. In view of the fact that the patient has not been strong enough to earn a living, we decided that colectomy should be performed.

**Colectomy.**—Preparatory to the operation a small amount of procain is injected about the ileostomy opening, which we now free from the skin, and then the ileum is completely divided. Each end we close and invert with a purse-string suture of silk. The wound is carefully cleansed and prepared and sealed with cotton and collodion. We will do the rest of the operation under light gas-oxygen anesthesia. The abdomen is prepared in the usual manner and a midline incision is made from the pubis to the umbilicus, extending slightly into the left rectus muscle upward for 5 cm. The wall of the colon is markedly infiltrated and thickened; the hepatic and splenic flexures are not quite as obliterated as in the 2 previous cases. We now free the parietal peritoneum of the cecum and ascending colon by sharp scalpel dissection. The mesentery is short and infiltrated, and does not allow the cecum and ascending colon to come out as readily as it should, and will therefore make the operation more difficult than in the previous cases. Also the powerful abdominal muscles of the man and the short mesentery make this procedure more difficult than in the 2 previous cases, which were in women with lax abdominal walls. We now dissect loose the short distal end of the ileum from the abdominal wall, and free the cecum from its mesenteric attachment, dividing between clamps as we go along so as to make the operation practically bloodless. The hepatic flexure is accessible and is easily detached. The greater omentum is now dissected from

the transverse colon, which is removed from its mesenteric attachment. The splenic flexure is somewhat higher and is retracted down into the posterior splenic fossa, so that it is less accessible. But, as you see, by dividing the parietal attachments, we bring the splenic flexure up to free it from the mesentery, again cutting between clamps. We now cut away the descending colon and sigmoid, in the same manner, without difficulty. The entire colon has been freed up to the upper rectum, which looks less infiltrated than the rest of the bowel, and will, therefore, be left intact. We next apply clamps at the upper rectum and divide the bowel with cautery. The upper end of the rectum is closed and inverted with a purse-string. On account of its short mesentery we will bring this closed portion of the rectum through the lower end of the mid-line incision instead of through a stab wound in the left rectus, as in the previous case. We now ligate all vessels with No 1 plain catgut, and, as you see, we obtain complete hemostasis with a dry abdomen and have lost practically no blood during the entire procedure. During the operation the patient has been given 2 quarts of physiologic salt solution by hypodermoclysis. His pulse throughout stayed between 80 and 90, and the patient is in excellent condition. We close the abdomen, but insert a few small fine capillary drains in the various layers, since our experience in the previous cases has been that it is next to impossible to prevent infection in the abdominal wall. We will now give this patient a blood transfusion of 500 c c by the direct Luer syringe method to allay secondary shock and to counteract the dehydration of the body which follows the removal of such a large amount of bowel from its mesentery.

**Blood Transfusion.**—As you see, we have three 100 c.c. Luer syringes and two needle cannulas of large caliber with a sharp cutting end. After distending the vein in the recipient's arm we transfix the vein with a cambric needle at its upper wall and plunge the cannula needle into the vein, using the cambric needle as a fixing point. We now put a second cambric needle through the skin and through a small shoulder opening made especially to hold the cannula in place so that it cannot

slip in or out of the vein. The same procedure is used on the donor. The blood is drawn up into the syringe, which has previously been washed out in physiologic salt solution and then in citrate solution. We now transfer these syringes, which you see in rotation, from the donor to the recipient, and each time a syringe is used it is washed out with physiologic salt solution and citrate solution to be ready for use again. As you notice, we transfused 500 c.c. of blood in ten minutes.

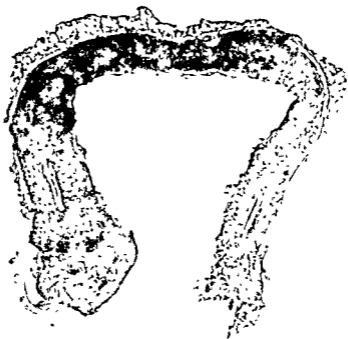

Fig. 231 —Colon removed in Case III, showing shortening with obliteration of the hepatic, splenic, and sigmoid flexures, dilated cecum and ascending colon, and narrowed transverse and descending colon, and polypoid condition of the mucosa

This method has the advantages that (1) in neither donor nor patient do you have to cut down on the vein; (2) virtually no reactions follow, and (3) it is rapidly done and requires no cumbersome apparatus. The less tubing and machinery used from the vein into the syringe, the less chance for clotting and difficulty. We prefer this simple method to any we have tried, and we have used it for about twelve years in a large series of cases.



The patient is warm, perspiring freely, and his color is excellent. We will now examine the parts removed at operation.

**Pathology.**—The specimen contains a fair amount of pericolonc fat. The cecum and ascending colon are markedly dilated. The colon, as in the previous cases, is contracted to about two-thirds of normal length. On opening the colon we see a picture of polypoid colitis. The mucosa (Fig. 231) is light pink and studded throughout with slightly raised polypoid masses from 2 to 4 mm. in diameter. The muscularis and serosa of the entire colon are thickened and greatly infiltrated.

*Note.* In microscopic sections through the colon the superficial layers of epithelium are missing. In places there are marked projections of epithelium with glands. There is an intense infiltration of the stroma of the mucosa by plasma-cells, eosinophils, and a few lymphocytes. Some of the lymph follicles are still present. The submucosa is fibrous and infiltrated with lymphocytes. In the muscular layers the fibers are somewhat atrophic, with occasional lymphocytes and eosinophils between the bundles.

The cases of ulcerative colitis shown here are the result of too long-continued medical treatment. When a definite diagnosis is made of ulcerative colitis and the patient does not show marked improvement after treatment for eight or ten weeks, the patient is better off with an early ileostomy to prevent the pathologic advance that occurs if too long medical treatment is attempted. With an early ileostomy the bowel may possibly be restituted to such a condition that colectomy will not be necessary. We have at present 3 patients who were treated by competent medical men with the most modern medical methods, without improvement. In fact, the patient on whom we operated this morning came to us eighteen months ago in a state of exhaustion and collapse almost beyond repair.

The etiology of ulcerative colitis is not well understood. In many instances streptococci are the predominant organisms in the washings and irrigations after ileostomy.

The chief criticism that can be made against long-continued medical treatment is that it is physically impossible to cure an ulcerative bowel as long as the intestinal contents are going through it, no matter how careful the diet and medication may

be. While the medical treatment is being carried on, which is usually from one to two years before the medical men decide that they cannot accomplish a good result, the colon is undergoing ulceration and infiltration—these processes are bound to produce narrowing of the lumen, contraction, and scar-tissue formation. When the healing process has finally taken place, the colon contains so many points of obstruction that normal physiologic function cannot be restored. Therefore we believe that the proper treatment for ulcerative colitis is early surgical intervention in conjunction with medical treatment, so that the bowel can be put at rest and cure effected before formidable and advanced pathologic changes take place. For instance, surgical intervention is indicated in a patient who comes to you with a history of recent diarrhea with bloody stools for a period of from four to six weeks, and on Roentgen-ray examination shows a typical infiltrated colon, and who has not been helped by medical treatment extending over a period of from six weeks to two months.

#### CONCLUSION

Ileostomy is the ideal first step in the treatment of ulcerative colitis after medical methods have been tried. If ileostomy is performed too late there may be improvement and a gain in weight as a result of the operation, but the patient is likely to continue to have blood and pus in the stools and to have chronic toxic absorption from the large infected area of bowel. If ileostomy alone cannot keep the infected field clean, possibly a combination of ileostomy and cecostomy would be effectual; in our next series of patients with ulcerative colitis we intend to give the method a trial.

In view of our recent experience with colectomy we believe that it is the only rational procedure to rid the patient of a tremendous focus of infection. It can be no more logical to leave from  $3\frac{1}{2}$  to 4 feet of infected, infiltrated bowel containing pockets of pus, than it would be to leave an abscessed tooth or an infected gall-bladder. We are not at all convinced that it would not be better to do these colectomies before the patient has had several years of absorption and damage to his vital organs from

the infected bowel. By amputating the colon down to the upper rectum and bringing this out into the wound we can irrigate and treat the 10 or 12 cm of remaining bowel, and then in four or five months, when it is healed, an anastomosis may be effected between the ileum and the remaining portion of the rectum

*Note.* Since these patients were presented, the second patient, in whom we opened the lung abscess, died forty-eight days after the operation from a terminal pneumonia. We do not believe that this fatality should in the slightest diminish our enthusiasm for colectomy in the treatment of ulcerative colitis, since the lung abscess and pneumonia occurred after the patient had completely recovered from the operation, and such a complication can occur with any other surgical procedure.

CLINIC OF DRS. EDWARD L. AND LOUIS D.  
MOORHEAD AND CHARLES LOUIS MIX

MERCY HOSPITAL

---

THE THYROID GLAND

Difference of Opinion Concerning Management of Thyroid Gland Disease—Presentation of the Medical Aspect of this Disease by Dr. Charles Louis Mix. Surgical Treatment—Technic Employed.

THE proper management of cases of thyroid disease continues to be a fruitful subject for discussion. There is still a wide divergence of opinion as to the proper treatment, whether it be medical, surgical, x-ray or radium, or practically no treatment except the removal of any foci of infection, especially in the nose and throat and attention to the general condition of the health of the patient. Good results are claimed by advocates of all these measures, and the clinician must be in a position to determine which method he is to follow in a given case.

This morning we are presenting for your inspection some 30 patients, who have been treated at our clinic in Mercy Hospital. They illustrate the various types of thyroid disease: cystic thyroid, adenomatous thyroid, exophthalmic goiter, toxic goiter, substernal and intrathoracic goiter, and carcinoma of the thyroid. A number of these patients have been operated upon and the results have been very gratifying. There are others in whom operation was not deemed advisable and 4 patients who have been prepared for operation, which will be done tomorrow morning.

We believe that these patients present both a medical and a surgical side for consideration and are, therefore, a problem for both the internist and the surgeon. My colleague, Dr. Charles

L. Mix, who is in charge of the department of medicine, will speak to you first regarding the medical management of these patients

DR CHARLES LOUIS MIX The thyroid gland is concerned chiefly, if not solely, with the iodine metabolism of the body. It finds iodine-containing bodies in the blood-stream and elaborates them into thyroxin. When the thyroid gland cannot get from the blood-stream sufficient iodine for the needed amount of thyroxin, it enlarges. Simple hyperplasia of the thyroid is merely a compensatory hypertrophy, and is exactly analogous to the hypertrophy of one lung, when the other lung has fallen a victim to fibrosis, or to the compensatory hypertrophy of the remaining kidney when its mate has been removed. Simple hyperplasia of the thyroid is an enlargement of the gland in its quest for iodine.

Hence it results that certain great areas of the world's surface poorly supplied with iodine-containing food are populated with men and beasts possessing enlarged thyroids. On the seashore, where sea-food containing an abundance of iodine is eaten by all, simple hyperplasia and simple hypertrophy of the thyroid are not found. The physical perfection of the ancient Greeks was largely due to their food-supply. Conversely, mountainous districts, remote from the sea, especially where granite abounds, are filled with unfortunate beings with enlarged thyroids. Switzerland possesses so many instances of thyroid disease that it naturally became the place in which thyroid disease was first intensively studied. The Himalaya Mountains and Thibet on their northern slopes are full of people with enlarged thyroid glands. Especially, too, in this country the Great Lakes region is a region of thyroid disease. The low iodine content of the water of the Great Lakes is the cause. Milwaukee, Chicago, Gary, Detroit, Toledo, Cleveland, and Buffalo are all cities in which goiter is abundant. Furthermore, many interior localities where iodine is absent from well-water suffer from the malady. This is quite true of the eastern half of the state of Washington, where goiter prevails.

Indeed, so true is it that hyperplasia follows when iodine is

deficient in food, that it has been possible to postulate the law that hyperplasia always begins when the amount of iodine in the gland falls below  $1/10$  of 1 per cent. In other words, all hyperplastic thyroid glands contain less than  $1/10$  of 1 per cent. of iodine; whereas all normal glands contain  $1/10$  of 1 per cent. or more.

In this connection one may be pardoned for speculating upon the relationship between thyroid enlargement and pregnancy. It is necessary that the mother provide her child with sufficient iodine to enable it to carry on a normal existence until it be able to secure iodine for itself. What if the mother finds iodine a scarce article in her regimen? Evidently thyroid hyperplasia will result. According to Quincke's old theory chlorotic anemia springs from the necessity forced upon the mother of storing enough iron in her liver to endow her child with iron sufficient for the first year and a half of existence. Why is not the simple hyperplasia of pregnancy another instance of nature's desire to be forehanded in the perpetuation of the human species? The hyperplasia of pregnancy, then, is a physiologic response of the pregnant mother to the need of an excess of iodine. The thyroid becomes hyperplastic in its quest for iodine.

Now and then it happens that the hyperplasia is in vain. The mother cannot get iodine enough both for herself and her child. The child is then born a defective—a being without the means of carrying on iodine metabolism, a child without a thyroid at all—a cretin. It is a logical inference that cretins will be most numerous in the very districts in which hypertrophied thyroids are the most frequent. Hence the abundance of cretins in Switzerland. They have been long known. The pagan Romans, finding these young defectives, defective both in body and mind, attributed their infirmities to their Christian religion, and opprobriously called them Chistians, Chrétiens, which becomes our word "cretin" of today. Not only do cretins come into existence in Switzerland; we have them in the Great Lakes region, and one can confidently assert that they will be found to be common in the Himalaya Mountain district and in Thibet.

property of increasing electric conductivity in the tissue cells, and since increased catabolism sets free increased energy, iodine becomes the great kinetic force in the body. This internal respiration, tissue oxygenation, increased catabolism, may be so intensive that the burned-up products of oxygenation cannot be scavenged fast enough to keep them out of the body. The result is the retention of waste products, or, expressed in different manner, the result is an intracellular acidosis. Hyperthyroidism and exophthalmic goiter, then, may be defined as an intracellular acidosis, due to a too rapid oxidation of tissue cells and a failure to scavenge waste-products with effective celerity.

In this connection one cannot forbear alluding to another ductless gland, the adrenal gland, which is also undoubtedly active in stimulating tissue metabolism. With Professor Cannon, despite adverse criticism of his ideas from Western Reserve University, I am inclined to view the adrenals as glands of emergency, glands to be used in periods of stress and of great strain, transitory but powerful in their effects. That the adrenals stimulate thyroid activity admits of no doubt. The Goetsch test is based upon this fundamental fact. That the adrenals increase the metabolic rate directly may be open to question, but that the internal secretions of the glands either primarily or secondarily cause increased metabolism, increased blood-pressure, pulse-rate, and respiratory rate is established. They also increase lymphocytosis and increase the perspiration. They cause vasomotor reactions. They lower the threshold resistance at the myoneural junction. Without the adrenals there is no heat production and there is inability to institute brain or muscular activity. Without the adrenals and their internal secretions life is impossible. The fact that it is the cortex which is essential to life in no way detracts from the statement that the adrenals are essential to life. The fact that hitherto we are in possession of only an extract from the medullary portion of the adrenals does not mean that the cortex of the gland possesses none. Until recently the cells of the islands of Langerhans possessed an internal secretion entirely unknown to us. Just as

we could predict, however, that the internal secretion of these pancreatic cells once found would obviate glycosuria, so now we can affirm that the internal secretion of the adrenal cortex once found will cure Addison's disease.

*The adrenal glands certainly do things calculated to help us in the great emergencies, when the physical ability to fight the hardest or run the fastest is all that will preserve us from death. Hence they cause to be poured into our blood-stream an increased amount of sugar; in other words, they cause hyperglycemia. Hence also they prevent muscle fatigue, and permit of greater physical strength by lessening the threshold resistance at the myoneural junction. Hence they have a profound vasomotor effect, redistributing the blood, drawing it from the viscera into the extremities and into the muscles in general. The adrenal glands, then, are of value in our emergencies.*

On the other hand, our thyroid glands are the stimulators of our steady, humdrum activities. They are, so to speak, our every-day clothes, while the adrenals represent our Sunday best. Our placid existence is presided over humbly by our thyroids. Our great emergencies are under the control of the adrenals. Emotional states stimulate the thyroid, but fear, anxiety, fright, and anger stimulate the adrenals vastly more. Thus the adrenals and thyroid are reciprocal and complementary—kindred in physiology. Hence it is not strange that the Goetsch tests should consist of an aggravation of thyroid symptomatology on the hypodermic administration of adrenalin.

The symptomatology of hyperthyroidism and exophthalmic goiter seems almost a deduction from the foregoing facts of physiology. If the thyroid and adrenals are for the purpose of carrying us through life and its emergencies, then an excess of either should cause increased heart action, tachycardia. Hence tachycardia becomes a cardinal symptom of increased thyroid activity. The heart is dilated somewhat, the apical tones are loud and ringing, the basal tones are unduly accentuated, and if the dilatation of the ventricular cavity be great enough to dilate the ring of insertion of the mitral flaps, their central edges no longer meet, and a leak or insufficiency results, and a func-



tional systolic murmur ensues. The toxins resulting from excessive thyroid activity may actually, not physiologically but anatomically, damage the myocardium. A true myocarditis may follow, with a secondary heart-block, or with auricular fibrillation and flutter, and as a result of true myocarditis edema and ascites may occur, with marked cardiac dyspnea.

A second cardinal symptom is the throbbing of the vessels, especially of the neck, due to the high pulse-pressure. Throbbing is nothing more or less than the visible evidence of a wide spread between systolic and diastolic blood-pressure. A systolic blood-pressure of 160 mm of Hg and a diastolic pressure of 60 mm inevitably results in throbbing. Throbbing reaches its ultimate expression in aortic insufficiency with a diastolic pressure of zero and often a systolic pressure of 180 mm or more. It reaches a high degree of visible expression in hyperthyroidism and exophthalmic goiter.

A third symptom, hitherto called cardinal, is exophthalmos. At present, however, this symptom serves rather to differentiate exophthalmic goiter from hyperthyroidism. For many years I have been convinced that two different toxins result from increased metabolism caused by different stimuli acting upon the thyroid. Thyroxin causes exophthalmic goiter, but it is altogether probable that another toxic substance, as yet not found, causes hyperthyroidism. The signs of exophthalmic goiter, taught in text-books, von Graefe's, the failure of the lids to keep pace with the eyeballs on following the fingers downward; Dalrymple's sign, or the wide interpalpebral fissure, Stellwag's, or the absence of winking, Moebius', or the inability to converge the eyeballs, are all mere extraneous things. One can see exophthalmos at a glance, and amuse one's self with these signs if he chooses. The main thing is the visible exophthalmos itself. When the bulging of the bulbs is too little to be evident, it simply does not exist.

A fourth symptom, always regarded as cardinal, is the distinctive tremor of toxic goiter. The oscillations are very fine, 8 or 10 per second, not at all like the coarse tremor of alcoholism or the intention tremor of multiple sclerosis. A physiologic ex-

planation of the method of causation of this tremor is not yet forthcoming.

Besides these four symptoms there is a fifth cardinal symptom—increased tissue metabolism. It is betrayed by the loss in weight, the wasting of the muscle masses, the atrophy, with the resulting muscular weakness and exhaustion. The weakness and exhaustion are doubtless due not alone to the atrophy of the muscle mass, but to the retention in the muscle-fibers of products of waste which they have failed to eliminate. At times the increased tissue metabolism is not evident because an increased appetite and an increased food consumption keeps the body in metabolic equilibrium. In these cases the determination of the basal metabolic rate becomes essential.

There are other minor symptoms which can be rapidly passed by. Chief of them, constituting almost a major symptom, is the nervousness and restlessness of the driven personality. Even a psychosis may result, usually a state of exaltation or mania, rarely a depression or melancholia, unless a state of exaltation or mania has preceded the depression. The genito-urinary apparatus also suffers. There is diminished libido in the male, a delay in or a complete absence of the menses in the female, and frequently polyuria. Sugar metabolism is increased with both hyperglycemia and glycosuria, doubtless due to a diminished tolerance for carbohydrates. The glycosuria of pregnancy, to my mind, will find its ultimate explanation in increased thyroid activity during the pregnant state, a temporary hyperthyroidism, as it were, made manifest by the glycosuria alone at times.

Vasomotor disturbances are marked and troublesome. A flushing of the face and chest is almost invariably present, but it is evanescent, coming and going, being especially apt to be present in periods of emotional excitement or embarrassment. With this is usually associated a marked tendency to perspiration, especially from the armpits. The surface moisture is responsible for increased electric conductivity of the skin, an old symptom of the text-books of thirty years ago. The vasomotor irritability is also shown very beautifully by der-

matographia, easily excited by even a slight scratch of the skin.

Gastro-intestinal symptoms are not uncommon. A reflex gastric hyperacidity has at times led even to the mistaken diagnosis of gastric ulcer. The increased metabolism, however, usually leads to an increase of appetite and an increased consumption of food. At times the toxins so irritate the intestines as to cause a diarrhea, the so-called safety-valve diarrhea of the old physicians, who did not try to check it because they noticed that patients were actually better after the diarrhea had run its course

The respiratory apparatus is also affected. The left vocal cord is apt to show an adductor paralysis or paresis from extra pull upon the left recurrent laryngeal nerve, occasioned by enlargement of the right lobe quite as frequently as by the left, the pull being just a little added tug on a trunk already a little tense because of its looping about the aortic arch. This adductor paresis is usually present before operation, and when sought for and found and the patient's attention drawn to it, the paresis following operation having been anticipated, the patient is not alarmed by it. Besides the adductor paralysis there is an effect upon the respiratory rate and rhythm. Expansion is diminished and frequently a non-productive cough is present

As aids to the diagnosis attention should be called to the Goetsch test, the determination of basal metabolism, and the differential count of the white blood-corpuscles. The Goetsch test is of value only in very limited borderline cases, where it is hard to differentiate a simple from a toxic goiter. Whenever the diagnosis is evident the Goetch test should never be used. The Goetch test is really an adrenalin sensitization test and is made by injecting 5 or 6 minims of a 1:1000 solution of adrenalin chlorid hypodermically. The test results positively when the pulse-rate is increased, the blood-pressure raised, when tremor and perspiration are caused, when flushing or pallor results, and when the pupils dilate. It goes without saying that it be-

trays a woeful state of ignorance to apply a Goetch test in a well-defined case of exophthalmic goiter

The basal metabolism test is also of value only in borderline cases. It is contraindicated when the blood-pressure is high or even much above 160 mm. of Hg. The result of the test is affected by age, the state of digestion, muscular activity and mental excitement, and should be given only when the three latter elements are under the control of the one giving the test. It must be remembered that infection, fever, anemic or leukemic states, and dyspnea, whether cardiac or non-cardiac, because of the increased muscle activity, also affect the result of the test. Diabetes mellitus also runs up basal metabolism. A high basal metabolism is of no prognostic value and does not contraindicate operations.

The white blood-count is of value, since in cases of hyperthyroidism and of exophthalmic goiter the lymphocytes frequently equal or exceed 40 per cent. A high lymphocyte count has some diagnostic value.

What shall be done in the way of treatment? This should be medical or surgical, as the case demands. In the first place simple hyperplastic and hypertrophic goiters, colloid hypertrophic goiters, and benign, normally innervated adenomatous thyroids, with or without colloid cysts, should be left alone surgically unless they disfigure or cause disagreeable pressure phenomena, in which case they can be easily removed. Simple hyperplasia and hypertrophy before the age of twenty-five years yield readily to iodine internally in almost any form. The syrup of the iodid of iron, syrup of hydriodic acid, or sodic iodid are equally good for prophylactic treatment among boys and girls, and during pregnancy prophylactic treatment is very essential.

If the thyroid is adenomatous it is potentially dangerous. I am gradually inclining to the opinion that an adenomatous thyroid is pretty much like a chronically inflamed appendix—better out than in. It can be easily removed without danger, and with its removal goes the possibility of sudden development of exophthalmic goiter or hyperthyroidism at some awkward moment.

If the thyroid is toxic, if it is causing symptoms plainly pathologic, it should be treated medically till symptoms are reasonably controlled, and then should be removed. Preliminary treatment in bad cases is very essential. There may be present an internal acidosis because of the increased internal tissue respiration. In this case the patient should be washed out with 3000 to 5000 c. c. of water daily, and alkalis should be given freely. If the patient is anemic he may be given a blood transfusion. If the heart is seriously disturbed in its rate, rhythm, and quality, the heart should be brought under the influence of digitalis before operation. The heart ought not to stop beating after an operation because of an inability on the part of the ventricles to close after diastole.

For mild cases of hyperthyroidism operation may not be necessary. Simple rest in bed for three weeks, quinin hydrobromid, 3 grains three times daily, or sodic bromid, 10 grains three times daily, may help much in slowing the rapid heart action. The diet should be non-protein, or at least largely carbohydrate. The use of the x-ray or of radium is of little or no value. Such use makes more difficult subsequent operation when required, and in itself has little or no effect in discouraging the elaboration of thyrotoxin. Dr Moorhead will speak more elaborately of the surgical indications for operation.

**DR. MOORHEAD: Surgery of the Thyroid Gland.**—The thyroid gland was the first of the ductless glands to warrant surgical interference. This is due in a large measure to its accessibility, the frequency of its lesions, and the well-defined evidences of its malformation. However, in spite of the marked progress in our knowledge of its pathology, and of the surgical indications and operative treatment of its lesions, many perplexing features bearing on the subtleties of its internal secretion are still attached to the study of the physiology of the gland, and we must look to the research workers in physiology for their solution.

**Exophthalmic Goiter.**—The symptoms which comprise this disease were ascribed for many years exclusively to overactivity of the thyroid gland with increased production and ab-

sorption of its secretion, and upon this interpretation of the disease has been based its surgical treatment. Of late many observers have been inclined to discredit the thyroid as the unique and all-important cause of the symptoms. Recent investigators seem to show a close connection in exophthalmic goiter between the thyroid and other organs. The persistence of the thymus has been attributed an important part in the pathogenesis of the disease, while various observers attach importance to the relationship which they consider has been established between the increased activity of the thyroid and the pituitary, pancreas, and chromaffin system, especially the adrenals.

Before entering into consideration of the treatment it is necessary to define the interpretation of the disease upon which are based the therapeutic measures advocated and practised at the present time. Without going into the intricacies of the discussion, it may be assumed that in this disease the structure of the thyroid shows fairly definite changes from the normal, namely, hypertrophy and hyperplasia of the thyroid parenchyma, that the gland secretes an excess of normal or of perverted material which enters the circulation, causes toxemia and secondarily influences the functional and organic conditions of other organs; that the usual type of the disease is represented by symptoms referable to this hyperactivity of the thyroid, modified, if at all, only to a minor degree by other organs, constituting for practical purposes a thyrotoxicosis or hyperthyroidism, and, finally, that the symptoms, as a rule, may be favorably influenced by operative measures limited to the thyroid.

*Operative Indications.*—There has been much discussion as to the indications for operative interference in exophthalmic goiter, and great divergence of opinion has been expressed. As a matter of fact, both the operative and non-operative procedures are essential in the treatment of the disease. It must be understood that the course of the disease is uncertain, and that occasionally, especially early in the disease, patients improve or recover without operation, at times without medical treatment. Non-operative treatment rarely affords more than

temporary improvement and usually requires periodic repetitions. If improvement is not marked and relatively lasting under medical treatment, operation is indicated unless definite contraindications are present. Moreover, early operation is indicated and unnecessary delay by unduly protracted non-operative measures is to be condemned, because the operative risk is much less in an early than in an advanced stage of the disease. The heart and other organs have not sustained permanent damage, and the course of the disease being usually progressive, it is probable in every case that operation will ultimately become necessary.

*Contraindications to Operation.*—Among these may be mentioned profound secondary changes in other organs, especially the heart and kidneys; marked dilatation of the heart, extreme rapidity and irregularity of the heart action, and evidence of severe nephritis if not improved by treatment. High metabolic rate; high lymphocyte count. Operation should be delayed until the subsidence of gastric crises, acute delirium, diarrhea, ascites, and edema of the hands and feet.

*Status Thymicolymphaticus.*—Persistent thymus has been particularly emphasized as a contraindication.

**Surgical Procedures in Exophthalmic Goiter.**—1. Ligation of vessels. In early cases with slight toxemia, in which modification of the blood-supply of the gland may re-establish its normal equilibrium. Severe cases in which temporary improvement may be obtained and enable a more radical operation to be supported. To supplement extirpation of one lobe with ligation of the superior vessels of the other.

2. Partial thyroidectomy is undoubtedly the most efficient treatment, operative or otherwise. But the observance of many details and the use of extremely good judgment are essential for its safe employment.

3. Thymectomy. Extirpation of the thymus has been recommended for the treatment of exophthalmic goiter, but too little is known of the indications for and results of the procedure for judgment to be passed upon it at the present time.

4. Intervention on the cervical sympathetic. Sympathec-

tomy was enthusiastically tried after its inauguration by Jaboulay in 1896. He practised section of the nerves; Jonnesco recommended section of the superior and middle ganglia with the intermediate nerve. The results were extremely variable and cures so exceptional that the method was practically abandoned.

5. *Injection into the gland of iodine and ether and other substances* was formerly practised, but was discarded as a dangerous procedure. Porter recommends the injection of boiling water.

*Anesthesia.*—The question of anesthesia is of great importance in operations for exophthalmic goiter. The choice of method of anesthesia is largely dependent upon the condition of the patient and the attitude of the operator in regard to the relative advantages of local and general anesthesia.

*Postoperative Care.*—In exophthalmic goiter the after-care is especially important. The patients are poor operative risks and danger persists for several days. Immediate care consists chiefly of rest in bed, quiet, fluids, and the relief of symptoms. Fluids should be administered freely, water being given by rectum either continuously or by injections about every five hours; if the rectum is intolerant, hypodermoclysis should be substituted. Sedatives, such as bromids, are to be given symptomatically; for excessive excitability and restlessness morphin may be used. Cardiac stimulants are often indicated and an ice-bag over the pericardium does much good to quiet the heart's action. Atropin in small doses is indicated if sweating is considerable. The patient should be under constant medical supervision and advice for a long period after operation.

*Simple Goiter.*—The indications for operative intervention in simple goiter are:

1. *Pressure disturbances:* The most frequent and important of these is pressure upon the trachea, causing dyspnea. Pressure upon the esophagus, at times causes dysphagia, but rarely of serious degree. Pressure upon the recurrent laryngeal nerve, usually unilateral, is not rare. It may cause hoarseness and cough. Pressure on the vessels which drain the head, neck, and upper extremity may cause cyanosis and edema. Pressure



upon the brachial plexus may cause neuralgic pains in the upper extremity.

2 Suspicion of malignancy: This is suggested by sudden rapid increase in size of goiter, especially if this is associated with pain, and if the patient is of advanced years

3. Deformity or discomfort: While the mere presence of a goiter does not in itself demand operation, the disfigurement, discomfort, and possibility of untoward developments in most cases render operation advisable even in cases of small adenomata and cysts

4 Abnormally situated goiter. Intrathoracic goiters, usually not recognized until pressure symptoms occur, should be removed as early as possible. Lingual goiters should be removed if they cause symptoms

5 Symptoms of toxemia. A slow chronic toxic condition which acts on the system somewhat like the acute toxemia of exophthalmic goiter may occur with any simple goiter, especially in those with single or multiple adenomata. These cases should be operated upon early, before changes have taken place in the heart, kidneys, and nervous system

**Surgical Procedures in Simple Goiter.**—A number of surgical procedures for the treatment of simple goiter at the disposal of the operator, whose choice must depend upon the individual indication of the case.

1. Excision: Removal of one lobe or one lobe and isthmus.

2 Resection. Removal of part of one or parts of both lobes.

3 Enucleation. Separation of a discrete nodule or cyst from the thyroid tissue

*Excision* or extirpation of one lobe is the safest procedure, and is thoroughly satisfactory in appropriate cases. In diffuse goiters the largest lobe is excised with or without resection of the other lobe. In multiple nodular goiters where the nodules cannot be enucleated excision is the operation. When the isthmus is diseased it is excised together with the lateral lobe

*Resection* is more dangerous than excision because the hemorrhage is greater and more difficult to control owing to the friability of thyroid tissue. In some large bilateral diffuse

goiters bilateral resection is employed to produce a symmetric result.

*Enucleation* consists in the separation of a discrete, localized, encapsulated tumor from the thyroid tissue. It is employed for cysts and adenomata.

*Operative Procedures.*—In the surgery of the thyroid there are certain general precautions which apply to all thyroid operations irrespective of the indications.

1. The avoidance of trauma to the recurrent laryngeal nerves.

2. Preservation of the parathyroids to avoid tetany.

3. Preservation of sufficient thyroid tissue to avoid myxedema.

There are certain specific precautions which apply chiefly to operations for exophthalmic goiter and toxic goiter

- I. Careful preparatory treatment until the symptoms are relatively quiescent so as to operate at a favorable time during the disease. All causes of increased metabolism should be removed if possible. A careful differential blood-count made, as a relatively high lymphocyte count is usually found in the severe cases. Attention to the heart, improving its action as much as possible. Rest in bed for a sufficient period of time is very important in the preoperative treatment.

- II. Proper selection of the anesthetic and the anesthetizer; careful watchfulness over the action of the heart and respiration during anesthesia.

- III. Diminution of shock by gentleness of manipulations.

- IV. Relative speed.

- V. Adequate exposure.

- VI. Minimum loss of blood and absolute hemostasis.

- VII. Curtailment of absorption by adequate drainage.

The earlier the diagnosis is made and operative measures used, the better the result will be. Failures are due to errors in diagnosis, delayed operation, insufficient operation, improper preoperative and postoperative care.

*Results:* 65 to 75 per cent. operated upon for exophthalmic goiter make a complete recovery. The majority of the remain-

ing 25 to 35 per cent are benefited, but some cases show no improvement, and death occurs in 1 to 4 per cent.

In the cardiovascular group of goiters, including the toxic adenomas and compensatory hyperplasias, better results are obtained

Deaths or severe reactions following operations are, for the most part, due to avoidable errors

**Description of Operation.**—Various incisions are used for the exposure of the thyroid, the transverse or collar incision; the U incision, the hockey-stick incision, which is made by omitting the upward prolongation of one side of the U incision, and the oblique incision, which follows the anterior margin of the sternomastoid muscle. In any surgical procedure on the thyroid it is essential that a liberal exposure be made so that all steps of the operation may be performed in an open field. This statement does not mean that the structures of the neck are to be divided without regard to their anatomic and physiologic functions. The thyroid surgery that I witnessed during my student days was usually attended by considerable hemorrhage, shock, and mutilation of the musculature of the neck, and the mortality rate was high. Rather unsightly scars and deformity resulted in many of the cases, and I regret to say that the same condition still prevails in many instances. In our work on the thyroid we have tried to avoid mutilation and the production of scar tissue to a minimum. If one keeps clearly before him the anatomic picture of the thyroid, surrounded as it is by its own anatomic capsule, and then by the surgical capsule, and that the operation is one of enucleation of the gland from within its surgical capsule, less damage will be done and better results obtained. The first time I was called upon to do a thyroidectomy was in 1891, when asked to conduct the clinic of my attending surgeon. The operation was for a large toxic adenoma. I assure you that great care was exercised to avoid traumatizing the parts, having unnecessary hemorrhage, and, above all, I did not want to lose the patient. The method of procedure in that case was quite similar to the method in use today, with the exception, of course, that surgical technic has become more refined and im-

proved. The incision (collar incision or some modification of it) is made through the skin, subcutaneous fat, platysma, and superficial fascia. The flap is freed by blunt dissection to the upper




Fig. 232.—(1) Incision through skin, superficial fascia, and platysma. (2) Incision through muscular fascia. (3) Ligation of superior thyroid artery. (4) Incision of surgical capsule of gland. (5) Ligation of inferior thyroid artery.

part of the thyroid cartilage and is held by a sharp retractor. The depressors of the thyroid are now exposed and are separated vertically by passing scissors between the sternohyoid muscles. At this stage of the operation instead of cutting across the sterno-

ing 25 to 35 per cent. are benefited, but some cases show no improvement, and death occurs in 1 to 4 per cent

In the cardiovascular group of goiters, including the toxic adenomas and compensatory hyperplasias, better results are obtained.

Deaths or severe reactions following operations are, for the most part, due to avoidable errors.

**Description of Operation.**—Various incisions are used for the exposure of the thyroid, the transverse or collar incision; the U incision, the hockey-stick incision, which is made by omitting the upward prolongation of one side of the U incision, and the oblique incision, which follows the anterior margin of the sternomastoid muscle. In any surgical procedure on the thyroid it is essential that a liberal exposure be made so that all steps of the operation may be performed in an open field. This statement does not mean that the structures of the neck are to be divided without regard to their anatomic and physiologic functions. The thyroid surgery that I witnessed during my student days was usually attended by considerable hemorrhage, shock, and mutilation of the musculature of the neck, and the mortality rate was high. Rather unsightly scars and deformity resulted in many of the cases, and I regret to say that the same condition still prevails in many instances. In our work on the thyroid we have tried to avoid mutilation and the production of scar tissue to a minimum. If one keeps clearly before him the anatomic picture of the thyroid, surrounded as it is by its own anatomic capsule, and then by the surgical capsule, and that the operation is one of enucleation of the gland from within its surgical capsule, less damage will be done and better results obtained. The first time I was called upon to do a thyroidectomy was in 1891, when asked to conduct the clinic of my attending surgeon. The operation was for a large toxic adenoma. I assure you that great care was exercised to avoid traumatizing the parts, having unnecessary hemorrhage, and, above all, I did not want to lose the patient. The method of procedure in that case was quite similar to the method in use today, with the exception, of course, that surgical technic has become more refined and im-

the fingers. The dissection is carried downward until the inferior thyroid vessels are encountered. These vessels are now clamped and ligated. The dissection should be carried as close as possible to the true capsule of the gland, and great care must be exercised to avoid injury to the parathyroids and recurrent laryngeal nerve. The isthmus, if it is to be removed, is now freed from the trachea, clamped close to the other lobe, and a continuous overhand catgut suture applied. The suture is drawn taut and tied as the clamp is withdrawn. All hemorrhage from any point must be completely stopped.

A small counteropening for drainage is now made in the suprasternal notch below the line of the incision, and a small gutta-percha drain inserted into the cavity from which the gland has been removed. The edges of the surgical capsule are brought together and sutured. The muscles came back to their normal position, since they were not cut across. The fascia is closed with interrupted sutures, the skin and platysma are sutured with a subcuticular suture of fine chromic catgut, and a dry dressing applied. In the closure of the skin incision a subcuticular suture will do away with the production of an unsightly scar. It is not necessary to cause a bad scar if a clean incision and a careful dissection has been made. In all operations upon the face or neck one should bear in mind the future appearance of the patient.

In the after-treatment of these patients we have them raised upon a back-rest as soon as they are out of the anesthetic and give them an abundance of fluids to drink to promote elimination. This position is much better for the patient, and they seem to like it in preference to having the head at a lower level than the body, as advised by some surgeons. The patients are allowed to be up in about one week. The drain is removed at the end of forty-eight hours.

Following operation the exophthalmic patient should have plenty of rest, good food, and such internal medication as the individual case demands.

In operations for the enucleation of cysts or adenomata the exposure of the gland is made in the same manner. Lately, for

ligation of both superior thyroid vessels in toxic cases where the gland is small, the exposure of the gland is made in the same manner, the muscles of one side retracted, the vessel exposed and ligated, and then the same done on the opposite side. By this method, if the condition warrants, one can proceed and resect or enucleate a portion of the thyroid, or if done as a preliminary ligation operation the same line of incision and flap may be used at a subsequent operation for removal of such a portion of the thyroid as is necessary.

## CLINIC OF DR. ARTHUR H. CURTIS

ST. LUKE'S HOSPITAL

### THE SELECTION OF ANESTHETICS FOR PLASTIC SURGERY AND SURGERY OF THE LOWER ABDOMEN

**Experience.**—Our views concerning the most satisfactory anesthetics are based chiefly upon experience at St. Luke's Hospital during the last ten years and may be summarized as follows:

Until within the last year we have employed nitrous oxid-oxygen or nitrous oxid-oxygen with a small amount of ether vapor as a routine anesthetic for private patients. Whenever gas has proved unsatisfactory we have tried not to stubbornly persist in its use, but have turned to ether. During all these years ward patients have received ether, administered in various ways.

To test the value of ethylene it was recently used in all private work throughout a period of six months. Various amounts of ether have been given with the ethylene.

Local anesthesia has been employed only in those cases in which it has been especially indicated. In extensive base hospital army service, however, we used this type of anesthesia more than any other, and therefore I have formed a rather definite opinion regarding its merits. With spinal and sacral anesthesia we have had no experience.

**Deductions.**—My personal choice of anesthetics may be summarized as follows:

Preoperative administration of morphin and atropin, with or without scopolamin, has found such wide acceptance as to require little comment, but just a word of warning regarding scopolamin is perhaps appropriate. We have repeatedly ob-



served the pulse drop to 50 or even 45 after its use, and have finally discarded this drug in fear of cardiac failure

Ethylene, at times aided by ether, is our anesthetic of choice in vaginal operative work, irrespective of its extent or character.

Ethylene may be used for lesser abdominal work, but ether, administered with the Ben Morgan machine, is usually our first choice in extensive abdominal operations upon the pelvic viscera. Despite years of relatively satisfactory experience with gas, we have come to the realization that ether is distinctly superior for work in this region because it affords complete relaxation such as we are able to secure with no other anesthetic.

Operations under local procain anesthesia are remarkably facilitated by hypodermic injection of a moderate dosage of morphin, *e g.*, 1/6 grain, given one hour before operation, followed by a second injection of 1/12 or 1/8 grain at the time the operation is begun. Ethylene, in addition, for analgesia is a very helpful adjunct. We have recently encountered a large series of unusually difficult operations in elderly women and have become increasingly impressed with the fact that the value of morphin-procain anesthesia has never been sufficiently recognized. Now that ethylene is available for analgesia during movements of special stress, it is planned to employ the combination of morphin and procain aided by ethylene in a much larger percentage of the cases.

## CLINIC OF DR. GOLDER L. McWHORTER

PRESBYTERIAN HOSPITAL

### CHRONIC APPENDICULAR COLIC WITH ASSOCIATED STOMACH SYMPTOMS

Presentation of a Case. Symptoms Relieved by Removal of Appendix. Theories as to the Cause of This Type of Distress. Factors of Importance in the Diagnosis of Appendicular Colic. Differential Diagnosis.

THE case which I have today illustrates chronic appendicular colic, which is only one of the pathologic conditions included under the term "chronic appendicitis."

This patient is an automobile mechanic, twenty-two years old. His complaint is distress after eating with pyrosis and loss in strength chiefly due to the fact that he is afraid to eat enough nourishing food.

Onset and Course.—He states that he was always well until three years ago, when he became troubled with distress in the epigastrium. He describes this as an uncomfortable feeling, covering an area the size of one's palm. It comes on soon after eating and lasts for varying periods of time, from a few minutes to several hours. He occasionally vomits. The distress has been present every day for the past four to six weeks. He is free at intervals, the longest being six months in the past three years. Coarse foods and cabbage are more certain to produce the distress. It is worse when he is constipated and after taking a cathartic. It is relieved by belching, soda, vomiting, and for a short time after taking food.

It was only upon physical examination, when I observed tenderness over the right lower quadrant, that a new complaint was obtained about distress in this region entirely overshadowed

by the stomach symptoms. This is a distress with tenderness and irregular attacks of pain of a sticking character, but never very acute. Sometimes it is associated with the epigastric distress. The pain does not last over five minutes. It comes irregularly and at variable times after meals. It may be relieved by flexing and rotating the thigh or massage of the abdomen in the region of the appendix.

The appetite is excessive. He states that he gets so hungry he could eat anything, but he is afraid to because it produces great distress. There has been a loss of weight of about 6 pounds in the last few weeks since he has had so much distress, and he is getting weaker and cannot do his work.

The past history is largely negative. He had a tonsillectomy ten years ago. Family history is likewise negative.

**Physical Examination.**—This is negative except for the abdomen. There is a sensitive area the size of the palm of the hand over the epigastrium, but this is not definitely tender. There is a tender area the size of a quarter over the region of the appendix.

With these findings one must think of a number of things which I will consider later. We find the laboratory reports of the blood and urine negative. There has been no blood found in the stool, which is normal. An Ewald meal one hour after ingestion shows an acidity of 56 free acid and 70 total acid. There are 100 c c returned. It is negative for blood. A fractional test-meal shows an acidity curve reaching its peak at the end of forty-five minutes and only slightly declining at the end of two hours.

The fluoroscopy of the chest was negative. The fluoroscopic examination of the stomach showed a good filling, pliable walls, good peristalsis, that the antrum closed off completely, and that there was a well-formed duodenal cap. The roentgenograms were negative.

From my experience I have found that fecaliths in the appendix may at times produce characteristic colicky symptoms, either limited to the appendix region or associated with colon or stomach distress. I have cured the local colic and partially

or completely relieved the stomach and bowel symptoms in a number of carefully studied cases by removing the appendix. It is my conviction that this patient has fecaliths in the appendix without an organic lesion of the upper abdomen. I believe the stomach symptoms will improve or entirely clear up by removing the irritating fecaliths in the appendix, and I feel certain that the pain in the appendix region will be relieved. On account of the epigastric distress I have promised the patient to explore the stomach in order to rule out a lesion in this region.

**Operation.**—I am making a high right rectus incision. The stomach and duodenum, as you see, are perfectly normal, with no evidence of an ulcer. The gall-bladder, the pancreas, and the kidneys are negative. There is nothing unusual felt about the abdomen.

Now we pick up the appendix. It is quite long, but with a short mesentery, which makes it difficult to expose. Near the tip I can palpate a fecalith about the size of a small pea and several small fragments of material near it. There is a definite thin so-called Jackson's membrane. There is nothing unusual in the technic of removing this appendix. I am using the cautery to amputate it, since I believe that there is less danger of contamination. The stump is now invaginated and there is no bleeding. The abdomen will be closed in the usual way.

I believe that the fecaliths which you see as I open this appendix (Fig. 234) were the cause of this man's localized tenderness and colic over the appendix region, and I believe the stomach symptoms were of a reflex nature. When he goes home I will give him no medication, and I expect that he will be back at work in a short time. However, it is well to instruct him in a general way as to the things he should eat.

In order to illustrate the relation of the time of onset of appendicular colic with the formation of the fecaliths, I wish to briefly cite another case. I operated upon this woman one year and a half ago for a pelvic condition. I carefully examined the appendix and found it normal, without palpable fecaliths. Recently, at a second operation for persistent profuse menorrhagia due to changes in the uterine wall, the appendix was

found still free, but the longitudinal artery near the tip was noticeably dilated. On palpation there was a fecalith about  $\frac{1}{2}$  inch from the tip. I removed the appendix and uterus. In addition to the profuse menorrhagia, the patient has had for the last three or four months definite short attacks of pain lasting ten or fifteen minutes in the region of the appendix. This mild colic would be followed, usually, by a dull ache and tenderness all day. There was no relation to food and the attacks did not come every day. They were rarely absent for more than a week and were worse when she was constipated. She has had complete relief since the operation.

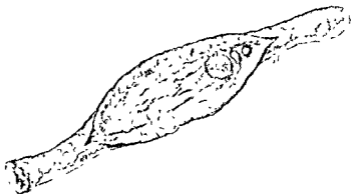


Fig. 234 —Fecaliths are present in the lumen of the appendix

I do not wish to imply that I believe all fecaliths in the appendix produce symptoms that will permit us to diagnose their presence, but in this case I believe that this fecalith produced symptoms soon after its formation.

On microscopic examination of the appendix in these cases where acute or subacute inflammation has not developed there is very little change. Usually there is a very slight round-cell infiltration of the submucosa. Where symptoms of inflammation are present clinically, we usually find the evidence of it in the appendix microscopically.

For several years I have been interested in chronic lesions of

the appendix as a cause of stomach symptoms and their possible effect on gastric acidity. I reported a case of acute appendicular colic with strangulation of the appendix due to an obstructing fecalith in the Surgical Clinics of Chicago in 1918. This case was seen by an internist of many years' experience, who stated that it was a colon colic and not appendicitis. He advised against operation. The confusing condition was an absence of demonstrable muscle rigidity and muscle spasm, but with severe colicky pains in the region of the appendix, which occasionally passed across the abdomen. The pain increased in severity and became almost continuous, still without any definite muscle rigidity or spasm.

However, there was a marked tenderness over the appendix region where all of the pains originated. I fortunately operated him as an emergency and removed a completely obstructed and strangulated appendix. Since then I have diagnosed recurrent appendicular colic in a number of cases followed by operative relief.

In some of these there were associated stomach symptoms in addition to the regional appendix distress. The stomach symptoms are similar to the type of distress seen in cases of duodenal ulcer, but they may occur without any demonstrable pathology in the abdomen. It has been recognized for years that chronic appendicitis and gall-bladder disease may produce these stomach symptoms.

There are several theories for the cause of this type of distress. Carlson has demonstrated that the contractions in the empty stomach are associated with hunger-pains, and that in the absence of these contractions hunger-pains are abolished. Increased severity of these pains, characteristic of ulcer cases, may result from hyperexcitability of the gastric nerves and local reflexes. In extragastric irritative conditions there may be increased long nerve reflexes which affect the stomach. Higgins has studied a group of cases complaining of hunger-pains, which he calls the stomach distress so characteristic in duodenal ulcer, and concludes that they may occur in chronic cholecystitis, chronic appendicitis, peptic ulcer, or in the absence of any

*demonstrable lesion* He believes that they may be due to a duodenal reflex resulting from absorption of bacterial toxins through the branches of the vagi or from a local inflammatory process in the duodenum

While recent studies have given to the acidity of the stomach a *secondary rôle in the production of these symptoms*, we usually find in the cases of chronic appendicitis with stomach symptoms a rather high and prolonged acid curve This is similar to the curve so frequently found in cases of duodenal ulcer, although even in ulcer there may rarely be an anacidity in the stomach

Spencer, Myer, Rehfuss, and Hawk have demonstrated that alkalis, which relieve this type of distress, act not by neutralizing the acid, but by relaxing the tetanic spasm of the pylorus and antrum, with a more rapid emptying of the stomach They also found a *stimulating effect on the human gastric juice secretion* from giving sodium bicarbonate solutions.

Gastric symptoms in chronic appendicitis, according to Aaron, may be caused by a reflex spasm of the pylorus with secondary changes in the secretion and acidity or, according to Fenwick and McGuire, the *gastric secretions may be changed primarily with the other changes secondary to the irritation of a hyperacidity*. Fenwick believes the constant excess of free hydrochloric acid gives rise to a spasmodic closure of the pylorus and also excites a violent gastritis often with interstitial hemorrhages. He believes that 12 per cent. of the cases of hypersecretion are due to disease of the appendix, and that there is usually an increase both in quantity and acidity when active irritation of the appendix is present. Paterson believes that the appendix influences the gastric secretion, but thinks it is due to intestinal stasis rather than to pyloric spasm Ochsner says that there is undoubtedly a contraction of the ileocecal valve during an acute exacerbation of appendicitis. This, in turn, may give rise to a contraction of the duodenal and pyloric sphincters, and in this way the normal passage of food from the stomach is impaired.

Long and short reflex nerve paths to the stomach from the

appendix and the intestines have been demonstrated clinically and experimentally. Experimentally I have noted this spasmodic contraction of the antrum and pylorus with barium meals after operations on the upper intestine in animals. I have found an increased secretion of the gastric juice from Pawlow stomachs in nearly one-half of the animals in which I produced experimental lesions of the appendix. The true acidity determined by the gas chain method was but slightly if any higher with the hypersecretion in these experimental animals. A definite decrease in the gastric secretion occurred only with emaciation and obstruction of the stomach or sickness.

I believe that the contour of the digestive curve of acidity must be influenced by the food and fluids present, the intensity and duration of the appetite and food secretion, the emptying time of the stomach, the gastric mucus and the saliva, and the regurgitation of the alkaline duodenal contents. It is interesting to note that a very low acidity is still sufficient for an optimum of gastric digestion. Boldyreff has shown the entrance of intestinal contents to be the most important factor in neutralization of the stomach contents.

I believe that lesions of the appendix, in addition to hypersecretion of gastric juice, may produce some disturbance of the factors concerned in neutralization of the acidity associated with the factors controlling the discharge of chyme through the pylorus. As a result stomach symptoms may occur.

In the direct diagnosis of appendicular colic the important things are the history, the physical examination, and the ability to rule out neighboring organic lesions.

In the absence of acute obstruction of the appendix the colicky pain due to fecaliths is usually mild and rarely lasts over five to fifteen minutes. It is intermittent and has no definite relation to food, but tends to follow meals. It occurs irregularly, but not every day, and is rarely absent for more than one or two weeks at a time. It is often followed by a persistent ache lasting the remainder of the day. It is usually worse during constipation, but may be brought on by a cathartic. In fact, cathartics I believe may cause the fecalith to produce acute



obstruction of the appendix. This fact is supported by one of the cases I have just mentioned. The milder colic may be relieved at times by pressure over the region of the appendix and by flexing the thigh. There may be persistent stomach symptoms, and at times pressure over the appendix may produce this distress. The colic or pain may be limited to the appendix, or it may extend across the abdomen with evidence of an irritable or spastic colon. There is tenderness on pressure over the appendix region at these times, and it may be constant. There may be no muscle rigidity or definite muscle spasm. Of course, there may be subacute inflammation or obstruction of the appendix associated with the attacks of colic. Here there may be muscle spasm and rigidity with leukocytosis and perhaps slight fever.

In differentiating other causes of colic one must rule out several conditions. Kidney and ureteral stone usually produce early gross or microscopic blood in the urine. Roentgenograms will usually show shadows of the stones. A cystoscopy may be necessary with the passage of a wax-tipped catheter. Pyelitis will show pus in the urine, fever, definite tenderness over the kidney, but a cystoscopy will clear up the diagnosis.

Salpingitis will usually produce a more persistent low pelvic tenderness, with sometimes an upper abdominal tenderness in the region lateral to the second or third lumbar vertebræ. I demonstrated this upper abdominal pain in salpingitis in this clinic in 1920. Pelvic examination will usually determine the cause.

Spastic colitis with colic will usually not be limited to the appendix region. It is more persistent, associated with indiscretions in diet, while examinations of the stool will show some variation from normal. Symptoms of an irritable or spastic bowel are often difficult to differentiate from appendicular colic necessitating careful study.

Even an acute appendicular obstruction by a fecalith, as I have previously shown, may simulate a bowel colic.

Partial obstruction of the cecum or ascending colon must

be ruled out by roentgenograms of the colon and examinations of the stool.

Where stomach symptoms are present, organic lesions must be ruled out by a good history, roentgenography, and examination of stomach contents and stool.

In conclusion, from my experience, I believe that it is possible to diagnose definitely a certain number of cases with fecaliths in the appendix producing local or reflex symptoms. This separates a clinical picture with a definite pathologic condition from the indefinite group of so-called chronic appendicitis. Since fecaliths are a constant source for inflammation, acute obstruction, and perforation of the appendix, early operation will definitely lower the still high mortality resulting from these conditions.

**Postoperative Observation.**—Three months after the operation the patient reports that he has no complaints. He has had no more "acid" stomach symptoms or colic in the region of the cecum since the operation. He eats almost everything and has been working hard for the last two months.

#### BIBLIOGRAPHY

McWhorter, G. L. Some Clinical and Experimental Observations on Gastric Acidity, Use of the Gas-chain Method *Amer. Jour. Med. Sci.*, vol. 155, p. 672, May, 1918.

Spencer, Meyer, Rehfuss, and Hawk: Direct Evidence of Duodenal Regurgitation and Its Influence Upon the Chemistry and Function of the Normal Human Stomach, *Amer. Jour. Phys.*, vol. 39, 459, February, 1916

Higgins: Clinical Significance of Hunger Pains; Gastro-intestinal and Gall-bladder Diseases, *Jour. Amer. Med. Assoc.*, vol. 82, 599, February 23, 1924.



## CLINIC OF DR. DAVID C. STRAUS

MICHAEL REESE HOSPITAL

### BRODIE'S ABSCESS

**Presentation of 2 Cases with Details of Operative Technic, Etiology, Pathology, Symptoms, Diagnosis, and Treatment.**

**Case I.**—The patient, an Austrian machinist, aged thirty-five years, Michael Reese Hospital, No. 50,671, was admitted to my service October 22, 1923 because of pain in his left thigh.

The present trouble began twenty years ago while the patient lived on a farm in Austria. At that time he developed pain in the thigh just above the knee, which came on without any apparent cause. This was associated with local swelling and fever. The involved area later became red. The doctor who was called to see him advised poulticing, and under this treatment the skin finally opened and a large amount of purulent material and some small pieces of bone escaped. The wound was allowed to close and no operation was ever performed. Since that time the patient had pain in this thigh more or less continuously. It was definitely worse after exercise and it was so severe at night that it interfered with his sleep.

The history otherwise showed nothing of interest. He did not remember any other illnesses and had never been operated on.

*Physical Examination.*—The patient was a large, well-developed man who did not look acutely ill. Physical examination was negative except for the left thigh. There was a dime-sized, pigmented old scar over the lower lateral portion of the thigh just above the knee-joint, where the old abscess had opened spontaneously. There was definite tenderness over the middle third of the thigh. The muscles were painful and

tender to slight pressure, deep continued pressure caused excruciating bone pain. This latter symptom, severe pain brought on by long-continued pressure over a bone, is characteristic of chronic inflammatory disease of bone.

The patient's temperature, pulse, and respiration were normal. The urine examination was negative. Blood examination showed a leukocyte count of 10,600, with a differential count of polymorphonuclears 60 per cent., small lymphocytes 40 per cent. Hemoglobin was 70 per cent.

From the history and the local findings it seemed clear that he was suffering from chronic osteomyelitis of the femur




Fig. 235—Roentgenogram of femur (Case I). This shows the thickening of the femur in the region occupied by the abscess (Ab). This thickening is due to thickening of the cortex by apposition of new sclerotic bone, which not only extends peripherally, giving the expanded appearance, but also extends and fills the marrow cavity for a distance of about one-third of the length of the femur, and is seen as an extremely dark area in the center of which the abscess cavity lies and can be seen as an area of lesser density. The epicondyle (Ep) was used as a landmark in locating the abscess cavity. The abscess lay at a distance of 20 cm from this point.

Accordingly a roentgenogram was made. This (Fig. 235) showed that somewhat more than the middle third of the entire length of the femur was moderately enlarged in diameter, due to thickening of the cortical bone. Not only was the cortex thickened and more dense than the other portions of the bone, but, in addition, the marrow cavity in this part of the shaft of the femur was completely filled with equally dense compact sclerotic bone. The periosteum was not definitely to be made out over this portion of the shaft of the bone, but one could see the irregular thickening of the cortex of the bone at this

portion was essentially due to irregular deposit of periosteal bone. This periosteal bone deposit was amorphous, that is, did not show any structure. Apposition of amorphous new bone is the most characteristic roentgenologic finding in osteomyelitis. Near the center of this area of sclerosed bone in the medullary cavity a localized area of lesser density about the size of the end of a lead pencil could be plainly seen (Fig. 235, *Ab*). This is typical of a localized abscess in a case of long-standing chronic osteomyelitis. This is what is known as Brodie's abscess. In order to rule out any question of syphilis, a Wassermann test was made. This was negative. As there was no question as to the correctness of the diagnosis of Brodie's abscess immediate operation was arranged for.

*Operation* (October 26, 1923).—Ether anesthesia. The patient was placed in the dorsal position on the operating-table (Fig. 236). While the limb was being prepared for operation I carefully measured on the roentgenogram the distance from the external epicondyle of the femur to the center of the area of absorption (abscess cavity) *Ep.*, *Ab*. This distance measured 20 cm. The ruler was then boiled up with the instruments. The thigh was raised from the table by supporting it on a sand-bag which was placed parallel to the long axis of the femur. The external epicondyle was now accurately located by palpation, and by placing the end of the ruler at this point the distance of 20 cm. proximal to the epicondyle was measured off on the lateral surface of the thigh and marked on the skin by making a short transverse scratch in the skin (Fig. 236). This transverse scratch mark was made sufficiently deep so that it could be referred to during the operation and used as a landmark. Using this transverse scratch mark as a guide a linear incision about 6 inches long was made over the lateral aspect of the thigh with its center at the scratch mark.

After cutting through the skin and superficial fascia the fascia lata was exposed and incised the entire length of the incision. The intermuscular space was sought between the flexor and extensor groups of muscles, and the femur was exposed by sharp and blunt dissection. In this manner the femur can be ex-

posed with very little trauma to the muscles and very little bleeding. In order to expose a wide area of the femur through this relatively small incision, I used a pair of retractors which I had specially constructed in 1912 for this type of work (Fig. 237). When these retractors were in place the lateral surface of this portion of the femur was widely exposed (Fig. 236).

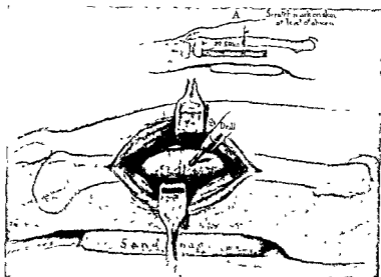


Fig. 236—Insert. This shows the thigh elevated on a sand-bag placed parallel with the long axis of the femur. Having located the epicondyle by palpation a point 20 cm. proximal to this was measured off on the lateral surface of the thigh and marked on the skin by making a short transverse scratch in the skin, as the roentgenogram (Fig. 235) showed this to be the distance of the abscess from the epicondyle. Using this transverse scratch mark as a guide, a linear incision about 6 inches long was made over the lateral aspect of the thigh with its center at the scratch mark. Note how the retractors hold the muscles strongly apart, giving unusually good exposure.

The exact level on the femur corresponding to the line drawn on the skin was noted. Then, using an ordinary machinist's drill fitted with a  $\frac{1}{4}$ -inch steel drill point, a hole was drilled in the shaft of the femur at a point 20 cm. from the lateral epicondyle (as shown by the scratch mark on the skin) and at about the junction of the anterior and middle thirds of the di-

iameter of the femur at this level, as this was the site of the abscess cavity as localized in the roentgenogram. The roentgenogram showed the cortical bone was extremely dense, but by means of so high-tempered a drill point it was easily penetrated. After the drill head had penetrated about half the thickness of the bone and no abscess cavity was come upon, the drill was removed and a new point of attack was selected about  $\frac{1}{2}$  cm. distal to the first. It must be borne in mind that in roentgenograms of the femur the images do not correspond to the exact



Fig. 237.—Special retractors used in operations on the femur in order to expose a wide area of the bone through a relatively short incision. The narrow portion of the blade is curved so as to encircle the shaft. The wide portion strongly retracts the muscles, as shown in Fig. 236. These are a modification of Höhmann's bone elevators.

size of the bone  $x$ -rayed, and are larger than normal proportional to the distance of the bone from the film, *i. e.*, being larger in proportion to the amount of soft parts between the bone and the film. In the case of a femur which lies deeply embedded in muscle the bone lies at some distance from the sensitive film and, consequently, is proportionately shown larger than its actual size. For this reason the measurements on the roentgenogram are slightly greater than the actual distances, and one has to allow for this in making his calculations. I, consequently, drilled a second hole slightly less than 20 cm. from the epicondyle. This time the drill penetrated the abscess cavity, as was evidenced by the fact that when the drill had penetrated



perhaps half the thickness of the femur a lack of resistance was suddenly definitely noticeable, just as is felt when one reaches the spinal canal in making a lumbar puncture.

The drill was removed and thick yellow pus escaped. A sample of this pus was taken for cultures. A probe was inserted into the abscess cavity, which was found to be circumscribed, as the roentgenogram had shown. The opening was enlarged by chiseling away the bone around the drill hole by means of a large curved chisel or gouge, thus converting it into a truncated cone-shaped opening. The cavity was lined with a thick granulation tissue membrane, as is characteristic in these cases. All this granulation tissue was removed and the cavity was further enlarged until all the walls consisted of healthy looking compact bone. The cavity was now filled with pure tincture of iodine and was firmly packed with plain gauze to check the oozing. The retractors were removed, allowing the muscles to come together up to the gauze, the incision in the fascia lata was closed by a few sutures of chromic catgut, and the skin closed with silk. The patient left the table in good condition.

The dressing was allowed to remain for forty-eight hours, when the packing was removed. The cavity was filled with balsam of Peru, a gutta-percha drain inserted, the cavity lightly packed with plain gauze, and a dry dressing applied. The post-operative care consisted in similar dressings daily. It is essential in these cases to be sure that the cavity fills from below upward so that no retention can occur.

The bacteriologic examination of the pus removed the day of the operation showed *Staphylococcus pyogenes albus* in pure culture. On the ninth day the stitches were removed. The cavity gradually became smaller and was completely filled up by November 28th, when the patient was discharged from the hospital. There was only a slight discharge from the wound, and he returned for daily dressings until healing was complete. The patient was presented before the clinical meeting of the Chicago Surgical Society held at Michael Reese Hospital December 7, 1923. At this time the wound was completely healed.

Case II.—A Russian laborer, twenty-three years of age, Michael Reese Hospital, No. 51,150, was admitted to my service November 9, 1923 because of pain in the right leg

The pain had been present in the winter time for the last three years and was described as located in the bone. The patient volunteered the information that the pain came on about one hour after going to bed, lasted most of the night, interfering with his sleep, and became alleviated on arising in the morning. Walking, he believed, relieved the pain. The pain extended from the knee to the ankle along the site of a scar in the skin, but was located deeply in the bone. In rainy or cold weather it became more severe; in bright warm weather it was less severe or disappeared entirely. There was practically no pain except during the winter months. It had been occurring during the three weeks prior to his entering the hospital about five nights a week. The pain had been so severe during the past three weeks that it had caused him to cry aloud during the night.

The condition dated back fourteen years, when, while a boy nine years of age, some one threw a chair at him, striking the right leg and making a bruise. The leg was only slightly painful until two months later, when he developed the typical picture of osteomyelitis. It was not until a month later when a sinus discharging pus opened spontaneously that he consulted a physician, who operated upon the leg. Two months later he had a second operation, as pus formed lower down. Three or four weeks later a third operation was done because pus formed near the ankle. He was confined to bed for one and a half years. After he began to walk he noticed that his leg bowed anteriorly, but there was no accompanying pain. He was entirely free from pain during the subsequent nine years until three years ago, when the pain recurred. The history presented no other features of interest.

Physical examination showed the patient to be a well-nourished, healthy man, who presented no abnormal findings except in the right leg. The lungs were particularly carefully examined for evidences of tuberculosis, due to the fact that the interval between the original trauma and the outbreak of the

osteomyelitis was so long that it suggested the possibility that the bone lesion might have been tuberculous. The lungs were entirely negative and nothing about the patient suggested tuberculosis.

The right leg was deformed, being strongly bowed anteriorly, the tibia was greatly thickened, and the skin over it discolored, thin, and shiny. An old scar extended from the knee to the inner




Fig. 238—Roentgenogram of tibia and fibula (Case II). This shows a marked thickening of the middle third of the tibia, with less marked thickening of the remainder of the tibia and of the fibula. This is due to marked thickening of the cortex both excentrically and concentrically. The marrow cavity is filled with compact bone for a distance of 9 cm., and at its center the abscess cavity (*Ab*) is seen as an area of decreased density. This lies at a distance of 19 cm. from the tuberosity of the tibia (*Tt*) which was used as a landmark to measure the location of the abscess.

malleolus. At the site of greatest elevation there was a localized area of tenderness on pressure. The findings strongly suggested a Brodie abscess, and a roentgenogram was ordered. The temperature chart showed a slight evening rise from normal, or slightly subnormal, in the morning, to normal or to 99.6° F. in the evening. The pulse and respirations were normal, being usually 68 and 18, even when the temperature was at its highest.

Urine examination was negative. Leukocyte count was 6800 and hemoglobin 80 per cent. Wassermann test was negative.

The roentgenogram (Fig. 238) showed a marked thickening of the middle third of the tibia, with less marked thickening of the remainder of the tibia and of the fibula. This thickening of the middle third of the tibia was due to great thickening of the cortex both excentrically and concentrically. At the site of greatest thickening this compact bone completely filled the marrow cavity for a distance of 9 cm. At the center of this sclerotic bone filling the medullary cavity there was an area of lesser density—a typical bone abscess—about 1 cm. in diameter. This was not as sharply circumscribed as a healed focus of tuberculosis which had to be particularly considered in this patient's case because of his age and the time interval that had elapsed between the injury and the first appearance of severe symptoms.

The diagnosis was clearly Brodie's abscess, and operation was arranged for.

*Operation* (November 19, 1923).—Ether anesthesia. The preparation and position on the table were the same as in Case I, except that the sand-bag was placed under and parallel to the leg. In this case the location of the abscess cavity was measured from the tuberosity of the tibia, and this distance was 19 cm. (Fig. 238, *T.t., Ab.*). A transverse scratch was marked on the skin over the anterior surface of the tibia at this distance from the tuberosity of the tibia, for use as a landmark. The skin over the tibia was now incised for about 6 inches, with the center of the incision at the scratch mark. With a periosteal elevator the skin was pushed to either side, held there by retractors, exposing the bone. A drill opening was made in the bone at a point 19 cm. distant from the tuberosity of the tibia corresponding to the location of the abscess on the roentgenogram. *The drill entered the abscess cavity!* Thick pus escaped. The drill was removed, some of the pus was taken for culture. The abscess cavity was lined with a dense granulation tissue membrane, just as is the rule in these cases. This was thoroughly

removed and the cavity enlarged until healthy bone was reached, and the operation was completed just as in Case I.

The pus removed showed a pure culture of *Streptococcus hemolyticus*. The cavity progressively diminished in size and the patient was discharged from the hospital January 10, 1924 with a very small wound, which was dressed at the Dispensary every other day and soon healed up entirely. The patient, just as is the rule in these cases, was entirely free from pain after the drainage of the abscess.

#### COMMENT

Chronic abscess of bone was first described in the literature by Sir Benjamin Brodie, and for this reason is often associated with his name and is called "Brodie's abscess." It may be of interest to quote Brodie's original report verbatim, as it is of unusual interest because of the accuracy of his observations and the detail of his case reports. In his original article which appeared in *The London Medical Gazette* for 1845, vol. xxxvi (New Series, vol. i), p. 1399, he states:

"In the year 1824 I was consulted by a young man, twenty-four years of age, under the following circumstances. There was a considerable enlargement of the lower end of the tibia, but the ankle-joint admitted of every motion and was apparently sound. The skin was thin, tense, and closely adherent to the periosteum. There was constant pain in the part, generally of a moderate character, but every now and then it became excruciating, keeping the patient awake at night and confining him to the house for many successive days. It made his life miserable and his system irritable, one effect of which was that it spoiled his temper and thus produced another set of symptoms in addition to those which were the direct consequences of the local malady. The disease had been going on for twelve years. He had consulted a number of surgeons respecting it, and had used a vast variety of remedies, but had never derived benefit from anything that was done. Instead of getting better, he every year became so much worse. I tried some remedies without any advantage, and at last recommended that he

should lose the limb. Mr. Travers saw him with me and agreed

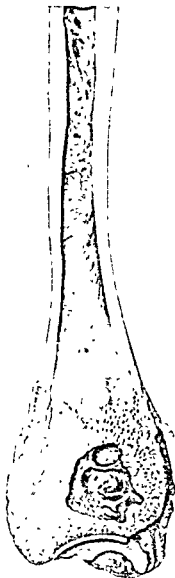


Fig. 239—Photograph (after Sir D'Arcy Power, *British Journal of Surgery*, vol. ix, January, 1922, No 35, p. 336) from a preparation "almost certainly the specimen which served as the text of Sir Benjamin Brodie's classical lecture delivered thirty-one years after the amputation had been performed" This was Brodie's first case.

in this opinion. Amputation was performed and the amputated tibia is now on the table. You will see (Fig. 239) how much

the lower end of it is enlarged and that the surface of it presents marks of great vascularity. The bone in the preparation is divided longitudinally, and just above the articulating surface there is a cavity as large as a small chestnut. This cavity was filled with dark colored pus. The inner surface of it is smooth. The bone immediately surrounding it is harder than natural. The examination of the limb explained all the symptoms: there was an abscess of the tibia, stretching the bone in which it was formed, or rather, if I may use the expression, trying to stretch it, and thus causing the violent pain which the patient suffered. On observing these appearances I could not help saying that if we had known the real state of the disease the limb might have been saved. A trephine would have made an opening into the tibia and have let out the matter. It would have been merely applying the treatment here that we adopt in the case of abscess elsewhere. You open a painful abscess of the arm with a lancet; you cannot open an abscess of the bone with a lancet, but you may do so with a trephine.

“About two years after the occurrence of this case I was consulted by another patient, twenty-three years of age, who had an enlargement of the upper end of the tibia extending to some distance below the knee. He suffered a great deal of pain, the part was very tender, and there were all the symptoms of chronic periostitis. I made an incision over the part, dividing everything down to the bone, and found the periosteum very much thickened. There was a new deposit of bone under the periosteum softer than the bone of original formation. This operation, as in other cases of chronic periostitis, relieved the tension and the pain, and the patient was supposed to be cured. However, about a year afterward, in August, 1827, there was a recurrence of the pain; the enlargement of the tibia, which had in some degree subsided, returned and it continued to increase. In the enlarged tibia there was one spot a little below the knee where there was exceeding tenderness on pressure. I need not describe the symptoms more particularly; it is sufficient to say that they bore a very close resemblance to those in the last case; the only difference being that as the disease had been of shorter

duration the pain was less severe, and that the tibia was affected in the upper instead of the lower extremity. I concluded there must be an abscess in the center of the bone, and applied the trephine to the tender spot. I used the common trephine made for injuries of the head, which, having a projecting rim or shoulder, would only penetrate to a certain depth. However, it enabled me to remove a piece of bone of sufficient thickness to expose the cancellous structure. Then with a chisel I removed some more of the bone. Presently there was a flow of pus in such quantity as completely to fill the opening made by the trephine and the chisel. It seemed as if the bone had been to a certain extent kept on the stretch by the abscess, and that as soon as an opening was made into it, it contracted and forced up the matter. The patient was well from that time, the wound healing very favorably, and he has never had any return of the disease.

“When the tibia is enlarged from a deposit of bone externally—when there is excessive pain, such as may be supposed to depend on extreme tension, the pain being aggravated at intervals, and these symptoms continue and become aggravated, not yielding to medicines or other treatment that recourse may be had to—then you may reasonably suspect the existence of abscess in the center of the bone. You are not to suppose that there is no abscess because the pain is not constant; on the contrary, it very often comes on only at intervals, and in one of these cases which I have related there was, as I then mentioned, an actual intermission of seven or eight months. After the disease has lasted a certain number of years, indeed, the pain never entirely subsides, but still it varies, and there are periods of abatement and of exacerbation.”

Brodie's abscess is always chronic and never acute. It is caused by bacteria of low virulence. Bacteria of high virulence cause the usual picture of acute osteomyelitis. It is only when the virulence is low from the beginning or has become low that a circumscribed abscess results. When a bone is infected with organisms of high virulence acute necrosis occurs, whereas in the case of organisms of low virulence a circumscribed abscess



may form, and the bone about it, instead of being of less than normal density, is stimulated and becomes sclerotic—nature's attempt to wall off a local focus of inflammation. The pyogenic membrane of granulation tissue that lines the abscess cavity is responsible for any destruction of surrounding bone in case the abscess cavity increases in size. The process is one of lacunar absorption.

The following organisms may be responsible for the formation of a Brodie abscess: *Staphylococcus pyogenes aureus* and *albus* are, by all means, the most frequent exciting organisms—according to Alexis Thomson in 84 per cent. *Streptococci* are less frequent causative organisms. The condition may be due to a primary tuberculosis of the bone being secondarily infected with staphylococci or streptococci. Typhoid bacilli are rare etiologic organisms.

It is striking how many years the causal organisms remain alive and virulent in a small abscess cavity walled off by the most dense kind of sclerotic bone. Kurt Müller reports the case of a man, sixty-three years old, on whom he operated for a Brodie abscess of the femur which dated back to an attack of osteomyelitis the patient had suffered with when he was thirteen years of age. Following the osteomyelitis he had felt well except for slight rheumatic pains until he was sixty-two years of age. During the year before Müller saw him the pains had increased in severity until they were intolerable. Pus removed from the abscess at operation showed *Staphylococcus pyogenes aureus*. Rabbits were inoculated intramuscularly with this pus and developed intramuscular abscesses, showing that in this case the staphylococci in the chronic bone abscess had remained alive and virulent for fifty years. Alexis Thompson is responsible for the statement that the longest period on record between the osteomyelitis and the abscess is fifty-seven years.

Brodie's abscess does not occur in the young, but usually in adult life, particularly in people of advanced years. However, it dates back to a primary osteomyelitis usually occurring in youth. In some cases the patient has completely forgotten about this infection. The causal osteomyelitis may or may not

have spontaneously perforated the bone. The inflammatory irritation ordinarily leads to firm encapsulation of the pus as a result of sclerosis of the surrounding bone. Occasionally minute sequestra may lie within the abscess cavity.

The abscess may be single or multiple, may be quite small, as in the 2 cases here reported, or may at times reach the size of a pigeon's egg or even a hen's egg. These large solitary abscesses usually occur in the cancellous structure in the metaphysis of a long bone, usually in the head of the tibia, less often in the femur or humerus. Brodie's first case occurred in the lower end of the tibia.

Brodie's abscess often exists for years and even decades without causing any symptoms. However, it is not uncommon to have periodic attacks of pain, particularly after bodily exercise and at night. The pains are drawing or boring in nature and are often mistaken for rheumatic pains. Occasionally the condition is associated with a low fever, hectic in type.

It is only when the bone is considerably thickened, so this can be made out by palpation, that the diagnosis can be made without the aid of the x-ray. Ordinarily a roentgenogram is necessary to confirm the diagnosis. While the roentgenogram may make one think of bone cysts or bone tumors, the diagnosis is ordinarily very easy on account of the osteosclerosis and periostitis.

If the cases are not operated on, the condition may lead to serious complications in rare instances, such as pathologic fracture or acute osteomyelitis. Finally, in case the pus breaks into the vessels of the bone, acute sepsis may result, with a fatal termination. Thus, it is obvious that even though the condition is a chronic one and of years duration, it is imperative to resort to operative interference as soon as the diagnosis is established.



## CLINIC OF DR PHILIP H. KREUSCHER

### MERCY HOSPITAL

#### CENTRAL DISLOCATION OF THE HEAD OF THE LEFT FEMUR WITH SUBSEQUENT DISEASE OF THE ACETABULUM DUE TO CONGENITAL LUETIC INFECTION

Central Dislocation of the Head of the Femur in a Girl of Twelve Years. Union Following Reduction. Later Development of Disease of the Acetabulum Due to Congenital Luetic Infection. Recovery Under Antiluetic Treatment.

IN reviewing the literature of cases of central dislocation I found no case reported under eighteen years of age. A number of the cases on record were diagnosed immediately, while 3 were not diagnosed until months after the accident. In 2 cases there was a fracture of the neck of the femur in connection with the dislocation.

The case which we present here for our clinic is a school girl, age twelve, who had been perfectly well up to the time of the accident. On January 14, 1921 she was struck by an automobile and thrown violently upon the sidewalk, injuring the left hip. The child was taken to her home and treated for a sprain for three days. Dr. Arthur C. Kleutgen, who was called in at this time, made a tentative diagnosis of fracture of the neck of the femur or pelvis and brought the patient into Mercy Hospital.

Examination showed a marked swelling and ecchymosis about the left hip. There was a shortening of  $\frac{3}{4}$  inch of the left leg, and there was great pain on an effort at rotation, especially outward rotation.

x-Ray examination showed a central dislocation, with the head of the femur in the acetabulum and a fracture of the ischium with displacement (Fig. 240). Digital rectal examina-

tion revealed the presence of the head in the pelvis, and several fragments of the fractured acetabulum could be distinctly palpated. On flexion of the leg on the thigh the examining finger could determine definite motion of the head.

The patient was immediately anesthetized and reduction was accomplished by the following method: With the surgeon's index-finger in the rectum and lying in contact with the head

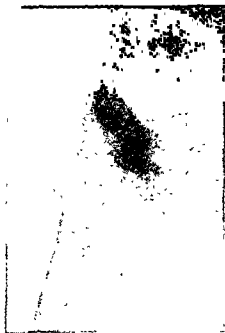


Fig. 240 —Traumatic central dislocation of the left femoral head with a fracture of the ischium

of the femur, traction was made outward on the upper third of the thigh, and considerably traction downward, with alternating inward and outward rotation. By simultaneous traction downward and outward, and pressure of the examining finger in the rectum, the head was quickly and easily brought into its normal position (Fig. 241). The patient was placed in bed with a Buck extension of 8 pounds on the affected limb, with very little abduction of the leg in the Travois splint.

This position was maintained for four weeks, at the end of which time a skiagram (Fig. 242) showed an almost complete

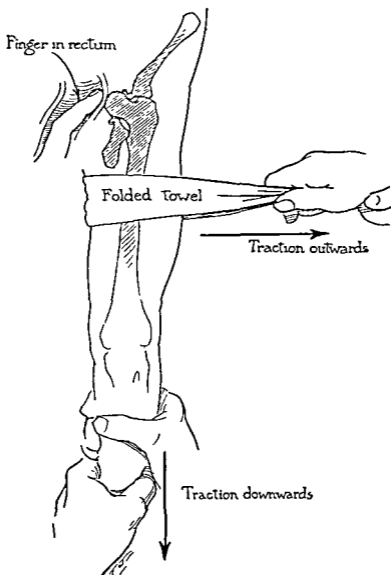


Fig. 241—Method used by author in reduction, showing surgeon's finger in rectum in contact with the dislocated head. Traction is made outward in the upper third of the thigh and downward with inward and outward rotation alternately until the dislocation is reduced.

reduction of the fractured ischium, as well as replacement of the floor of the acetabulum, with the femoral head in the normal

position. The measurement of both extremities showed them to be of equal length. The patient got about with the aid of a crutch for three weeks after leaving the hospital, and at the end of that time she was permitted to return to school and walk about normally.

Eight months after the accident the child was again brought to Dr. Kleutgen showing a very decided limp, and a marked ro-




Fig 242 —Skiagram taken immediately after reduction showing the head in normal position.

tation of the left hip and a curvature of the spine. Physical examination at that time showed a marked fixation of the hip-joint, a tilting of the pelvis, but no actual shortening of the extremity as compared to the right leg. *x*-Ray examination showed a rather extensive destruction of the upper half of the acetabulum and a flattening and partial destruction of the weight-bearing portion of the head of the femur (Fig 243). Our tentative diagnosis was tuberculosis of the hip following trauma.

In going over his records Dr. Kleutgen found that he had delivered this child, and that subsequent to delivery there presented very decided symptoms of congenital syphilis. The doctor's insistence at that time upon treatment for congenital syphilis caused the parents to call in counsel, who disagreed in the diagnosis, and took the child in charge without administer-

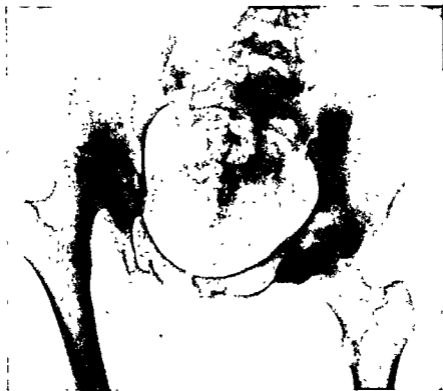

Fig. 243 —Marked tilting of the pelvis with destruction of the upper half of the acetabulum and flattening of the head of the femur due to luetic disease of the hip-joint.

ing any antisyphilitic treatment. Having this history, a blood Wassermann was taken, which proved to be 4+ positive. The patient was immediately put under antiluetic treatment, was again placed in bed with a Buck extension for a period of five weeks, at the end of which time the tilting of the pelvis had entirely disappeared, as shown in Fig. 244, but with a marked flattening of the head of the femur. Examination showed a



perfectly movable hip-joint. The patient was able to put weight upon the extremity without pain and was permitted to go home.

Now (two and a half years after the appearance of the hip disease) the patient is still under observation, but gets about normally with free and painless motion in the hip-joint, with

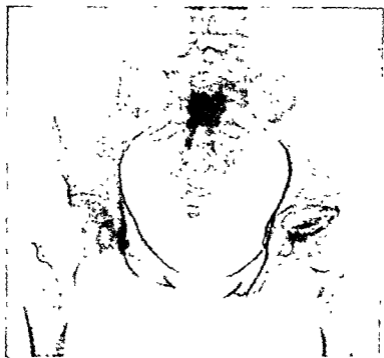

Fig 244—The pelvis has been straightened by a continued Buck's extension for three weeks. Note the marked destruction and flattening of the head of the femur

no tilting of the pelvis, and from the skiagram (Fig. 245) is beginning to have marked regeneration in the head of the femur and acetabulum with slight lipping of the upper end of the acetabulum to insure against any subsequent dislocation upward. The fractured pelvis as well as the fractured ischium is completely healed and the child is symptomatically well.

In reviewing this case one is impressed with five important facts:

First, that a central dislocation of the hip is possible even in children two or three years before the ossification of the bones is complete.

Second, that a very simple method of reduction as outlined suffices for the reduction of a dislocation of this type when it is



Fig. 245.—Two and one-half years after the institution of antiluetic treatment showing the complete healing of the fractured acetabulum and ischium and the beginning re-formation of the head, with slight lipping at the upper end of the acetabulum.

seen within a few days of the accident. We must remember that if the head is permitted to remain in its dislocated position until fixation has occurred, then nothing short of an open operation will accomplish reduction.

Third, this case teaches us the value of keeping an accurate record of all our patients, and even though by conscientious recommendation of such treatment as is indicated, the case is

lost to the clinician, we occasionally have the great satisfaction of having our diagnosis proved correct at a later date

Fourth, that we have no way of telling when a congenital syphilis will make its appearance or will localize, as it did in this case, and we must insist upon such treatment as is indicated.

Fifth, that under antisyphilitic treatment marked destruction of bone and joint surfaces can be restored to normal condition.

## CLINIC OF DR. WILLIAM M. HARSHA

ST. LUKE'S HOSPITAL

### CARCINOMA

Presentation of 4 Cases of Carcinoma of the Tongue and 2 of Carcinoma of the Stomach. Treatment Employed in Each Case. Campaign for the Study of Cancer.

I HAVE for presentation this morning 6 cases, 5 of carcinoma and 1 simulating carcinoma, 4 of the tongue, and 2 stomach cases. These cases are of interest because of the efforts now being made to impress upon the laity as well as the medical profession the necessity of early diagnosis; also the need for more frequent exploration in obscure cases.

**Case I. Carcinoma of the Tongue.**—This patient is a negro, aged sixty, a mail carrier by occupation, who first came under observation in July, 1923. His family history is negative.

*Personal History*—He had lues at eighteen years of age, for which he has had treatment more or less continuously up to the present time under the supervision of a good physician in his home town.

*Habits.*—He drank very little, but smoked a pipe, having the pipe in his mouth more or less all through the day.

There was a decayed tooth on the right side which first started an irritation. The patient first noticed the growth about May, 1922. He had no treatment at that time for the tongue, but was operated upon July 16, 1922, with excision of the growth, but no removal of the glands, and no x-ray or radium therapy following operation. There was no pathologic report.

In February, 1923 the growth on the tongue recurred, with a right cervical gland enlargement. Radium needles were then used on the tongue and in the cervical gland by Dr. W. T. Harsha. The tongue has been and is now free from disease, as you can see. (Patient exhibited.) The gland, however, became cystic, and on aspiration yielded about 2 ounces of fluid. It then began to slough, and the disease has spread to the vascular areas, from which there have been frequent hemorrhages requiring to be packed. About July, 1923 the glands enlarged on the left side of the neck, which is not uncommon in right-sided cancer of the tongue. This was when he came under my care. I have used only *x*-ray treatments, with continuation of mercury and iodids.

*Comment.*—As probable exciting causes there was a jagged tooth, leukoplakia, and pyorrhea. The glands were not removed at the first operation. The patient was luetic. The prognosis is absolutely unfavorable. Tongue cancer if untreated usually goes on to fatal termination in about two years. The patient's usual weight when well was 150 pounds. He now weighs 144 pounds. Within the last month he suddenly developed dysphagia. I thought it might be due to sudden enlargement of mediastinal glands. *x*-Ray showed no apparent pressure and he got over his trouble promptly under bromids.

**Case II. Carcinoma of the Tongue.**—This patient, Mr. L., was seventy years old at the time of his operation. He is an art decorator, with a negative family and personal history.

His habits were moderate. He did not drink much, but smoked a pipe a great deal.

He had a bad tooth extracted ten years before the start of his trouble, and a snag was left, and to that snag he attributes the start of his irritation which caused a growth some years later. He was operated in October, 1918. For a year before his operation the growth did not bother him much, and he had no treatment for it until he came to me, when we excised a portion for diagnosis. The growth was on the under side of the tongue on the left—the side the snag was on. We excised the

growth, with wide margin, and the glands. No Wassermann examination was made because he was a man of exceptionally good habits and was in good health.

Following the operation he had radium treatment immediately after, and again a month or so later, locally. He had two severe hemorrhages during his convalescence and was in the hospital for four weeks. Hemorrhage, you know, is one of the complications of operations upon the tongue, and his hemorrhages were rather severe. It is hard for him to get the tongue up, but he talks pretty well.

The pathologic report from the hospital was carcinoma. The glands all around, submental and lateral, were removed freely. His blood at that time was not impaired much and has not been since, and he has done very well.

**Case III. Carcinoma of the Tongue.**—This man is past seventy and his occupation is that of waterpipe extension, and work of that sort. Family and personal histories are negative.

*Habits.*—He did not drink very much, but smoked a pipe a good deal. His Wassermann reaction was negative.

This man also had bad teeth up to the time of his operation. He was operated upon by my associate, Dr. Seifert, but he did not remove the glands. He was operated with the electric-cautery knife. The patient says he first noticed the growth in March, 1919, but Dr. Seifert thinks it was there earlier. He went to the drug store to get something to wash the mouth with, but this did no good. His hemoglobin was then 62 per cent. and he weighed 135 pounds. He was operated upon in April, 1919, with excision of the growth, but no removal of the glands. The laboratory report was carcinoma.

Soon after this, radium treatment was given by Dr. Simpson once or twice locally, but it was never used in the neck. The patient left the hospital in two weeks, having had one hemorrhage, which was not difficult to control.

He now weighs about what is normal for him and his blood condition has improved greatly. His hemoglobin is now 88

per cent. and he has in other ways improved in proportion. The growth was burned away quite freely, as you can see.

**Case IV. Carcinoma of the Tongue.**—This lady was kind enough to come in so that I might exhibit another case of cured carcinoma of the tongue. She was operated in April, 1901, and is the longest cured of any tongue case I have had. At that time she was a widow of two years, a housewife, and had a young child. The symptoms were those of a raw scalding sensation around the mouth and tongue. She first noticed the growth about a month before her operation. It was excised with the glands underneath, submental and lateral, perhaps not as extensively as we do it now, but apparently enough.

The pathologic report from Dr. Hektoen was carcinoma. There was no x-ray treatment following the operation and we had no radium at that time. The patient now weighs about 144 pounds, and at the time of operation weighed 128 pounds. Her strength was not impaired as much by the growth as by the strenuous life she had led during the few years preceding its development. She is now in excellent health.

As you can see, she has the remains of a tongue and her children have put her through some stunts to test her speech. She lisps a little, but otherwise her speech is not affected.

**Comment.**—You will notice that some of these cases are old. Case III does not know just how old he is, but he thinks he is seventy-two. We all know the older the patient, the less rapid the metastases and the less rapid the growth. Case II was seventy at the time of the operation; he is seventy-five now. You will notice, too, that nearly all of them had some irritating cause. Mrs. P. did not so far as I can recall. One thing is certain about cancer, and not many things are—irritation has to do with the start of it. We have many people who believe that carcinoma is an infection. Of course, the cause is debatable. Dr. Ochsner is a strong believer in infection. Against that, among the many thousands of cases operated for carcinoma and attended by nurses, I do not know of one that can be ascribed with certainty to transference from

one to another. Efforts to so transfer them have almost always been failures, while metastases are very easy in the same patient. The system seems to be sensitized to carcinoma in a way, or at least the immunity normal people may be said to have is lost; and what contributes to the state that invites carcinoma is an interesting problem which perhaps some Columbus or Banti will discover. We know that chronic irritation will often start the trouble. By analogy, we know that tubercle bacilli, if we have an infected tongue, will be transferred and metastasize and produce an overgrowth of tissue like that in the place where it metastasizes. In the bone we have a stimulation of pathologic cells of the bony type. If it is in the liver or the lung we have overgrowth of liver or lung tissue, plus tuberculosis, but if it is carcinoma in metastasis, it develops the same type of cell as at the starting-place, not typical of the liver or any other organ that may be invaded; and that is an argument against the infection or germ theory. Whatever it is that gives the cell the power to grow in any tissue and supplies that growth with typical carcinoma structure is the part we cannot yet understand.

In 2 of our cases the glands were not removed at operation. The first case is an unfavorable one and the patient will go on to death in spite of anything, unless *x*-ray therapy will do some good. The case that got well without glandular involvement is past seventy and had radium and *x*-ray treatment at the start. Now everyone advises removal of the glands at once. Crile and others have pointed out the importance of the collar of glands around the neck which catches the infection. Since Crile, Butlin, and Bloodgood, who have been pioneers in this type of operation, have impressed the need of free glandular removal we have had better results; and we will have still better results when we get early operations.

Three stages are recognized in carcinoma of the tongue or any other place. First, the operable stage in which there is no metastasis. We all believe that cancer is a local manifestation at first. The idea of it being a blood disease has prevented early operations for many years, and the sooner we get rid of



that idea the better. The second stage is the middle stage, where the cancer has progressed to a considerable degree and probably has metastases. They are probably present if not yet palpable. In this second stage we are justified in doing operation with excision of exposed glands. This may remove the growth at the local site and effect a cure, while metastases may go on to a fatal termination. However, these probably will not be accompanied by the odor and pain that occur in unoperated carcinoma. Then there is the third stage, such as I have shown you, which was clearly inoperable, and in these  $x$ -ray or radium may be of some benefit; at any rate, it is our sole hope.

The fate of the carcinoma case at present should be better than it ever has been because of the additional means of treatment which we have in  $x$ -ray and radium.

**Case V. Carcinoma of the Stomach (Inoperable).**—This man is sixty-one years of age and by occupation a foreman of a department in a packing plant, with negative family and personal histories.

His habits are good, moderate in all things. He drinks and smokes moderately.

His maximum weight has been 132 pounds. He came to the hospital six weeks ago for examination, and that was the first time we saw him. He had been under treatment for indigestion, but had no particular pain, discomfort, or hemorrhage, and there was not much complaint of anything except the gradual loss of weight and inability to eat freely. He then weighed 112 pounds. He had grown weak. He had gradually regulated the amount of his diet by the degree of comfort in his stomach, so he was not eating much.  $x$ -Ray examination at that time showed extensive growth contracting the stomach. It was considered best not to do an operation at this time, and he has had deep therapy. I had an  $x$ -ray picture made this morning which will show not a great deal of change from that taken six weeks ago. He has maintained his weight since his first treatment and has been more free from gas eructations. He has been dieting with respect to his capacity. We have urged

him to take liquid food every three hours because he cannot get enough nourishment in the ordinary intervals between meals. This is about all we can say. He has maintained his body weight and strength and has less impairment of digestion than he had before the x-ray therapy. Whether this is due to his taking food in smaller amounts or whether it is due to improvement of the stomach I cannot tell. I think he had a full dose; he was under treatment one hour and will have another deep x-ray treatment next Monday. There is no palpable tumor.

**Case VI.**—Mr. H. This is a patient from out of town who was kind enough to come in. He was sixty-one years old last March, and by occupation is an operator of a woodworker's machine in a shop.

*Family history* negative as to any malignancy.

*Personal history* was good until he had an injury in the mill, which we know as a "kick-back," July 26, 1922.

*Habits* are good. He drinks a little and smokes a good deal, but has not been excessive about anything.

He was knocked out by a blow over his stomach. It took his breath, made him dizzy and shaky for some hours. He was home for a while, and after four weeks returned to work, but only worked for a few days. He weighs 125 pounds now. A year ago today he weighed 98 pounds, when he first came to the hospital.

His symptoms were pain—note the difference between these 2 cases. I am contrasting them because this is not a case of carcinoma. He had marked rigidity all over the abdomen, much more muscle resistance than the other man, had a stooped gait, reduction in weight, and was very sick. When he came to the hospital he could not stand up very long. He came in with a diagnosis of carcinoma of the stomach after three x-ray examinations by different men. It being an industrial case, the question of settlement on account of total disability came up. The differential diagnosis was the point. I did not know but that he had carcinoma of the stomach. Everyone said he had, all the x-ray men thought so; and he had many symptoms. My

experience has been that carcinoma of the stomach in most cases is one of the most benign ailments as to pain of anything I know of so serious import. This man when he came in presented some symptoms that carcinoma does not usually present. He had marked pain, cramps, rigidity, and tenderness. He agreed to an exploratory operation, and we operated on October 14, 1922. We found the stomach  $\frac{1}{2}$  inch or more in thickness in the posterior wall, indurated, and the whole stomach surrounded



Fig 246—Roentgenogram taken one year ago. Note marked obstruction at the antrum and pyloric region and the great immobility.

by perigastric adhesions which bound everything down, especially at the pylorus and antrum. The adhesions were broken up and the organ freed.

The x-ray examination (Fig 246) before he came to the hospital showed marked obstruction at the antrum and pyloric region and great immobility. You will notice a very great difference between the x-ray picture (Fig. 247) of the stomach today and that of a year ago. I could not tell with certainty

even after operating on him whether he had carcinoma of the stomach or not. He had the thickening, the induration, and if he had carcinoma I figured that it must have been present before the injury, but he maintained that he was entirely well up to the time of injury. That suggested trauma alone.

We loosened up the stomach, and dieted him and he left the hospital on October 24th. On December 11th he went to work and has been working ever since. You can see the dif-



Fig. 247.—Roentgenogram taken on day patient was presented in clinic. Note the contrast with Fig. 246.

ference in the two pictures. Evidently there was no carcinoma in this case. I have talked to Dr. Jenkinson about the  $x$ -ray report; and he says there are still some adhesions around the pyloric end of the stomach. These adhesions are likely to lengthen out and, after a while, become less and less disturbing. He has had no trouble with indigestion since that time unless he eats too much.

The main thing in this case hinges on the differential diag-

nosis. I felt that there was enough uncertainty about it to warrant an exploration, and I believe we should make more exploratory incisions. I am sure we should do this if we are going to make early and better diagnoses in carcinoma of the stomach. It is the early and the hard diagnosis that we have to make if we are going to make a difference in our mortality records. The conditions, as I said, are better today because of the facilities for early operation, because of the x-ray and radium, because of the various tests, and the results from treatment are much better than they have ever been before in carcinoma. I think only a little over thirty years ago Professor D. Hays Agnew said he had never cured a carcinoma of the breast. Then came Halsted, of Johns Hopkins, and showed us how to do a radical operation, and now everybody has cured cases.

The late Dr. Murphy, several years ago, showed that about 20 per cent. of carcinomata of various kinds go on to fatal termination without metastases; but one cannot tell when metastasis will happen and I believe we should take out glands wherever we can. In the last century the mortality from carcinoma of the tongue was very high, depending upon the time at which operation was done and the age of the patient. The mortality is now about 15 to 17 per cent. Bloodgood thinks 98 per cent. of all cancers of the skin can be cured if taken early. Of course cancer of the skin does not metastasize like some other forms. At the Mayo Clinic they have, I believe, over 20 per cent. of cures of cancer of the stomach. Bloodgood thinks that 86 per cent. of all breast cases can be cured by early operation and 90 per cent. of carcinoma of the lip.

The campaign for the study of carcinoma began actively in 1899 by the establishment of a research hospital by the late Roswell Parke, at Buffalo, who used to be here. The next step was the establishment of the American Society for the Control of Cancer, and that organization has an excellent record. Now there are other societies all over the world. If carcinoma can be reduced like diphtheria, where we have reduced the mortality to almost nothing, if this campaign is like the campaign against typhoid which made clean water, then it is worth while. When

I came to Chicago the river flowed into the lake and we could not catch a self-respecting fish within a mile of the river mouth; but we could catch typhoid any place in town. Now we have to go out of town to some health resort to catch typhoid fever and we can catch fish in the river. When I came to Chicago the death-rate from tuberculosis was nearly four times as high as it is today. The better housing, the better water and better food supply, fresh air, and everything that goes to keep a population healthy is well worth while. If this campaign against disease goes on for a few years the people will be like some prohibition officers—they will not catch anything.

**Note.**—Case I (carcinoma of the tongue) died December 24, 1923; Case V (carcinoma of the stomach) died December 11, 1923.



## CLINIC OF DR. EDWIN M. MILLER

PRESBYTERIAN HOSPITAL

---

### LESIONS OF THE BREAST ASSOCIATED WITH A DISCHARGING NIPPLE

**Cases Presenting Discharge from the Nipple May Be Classified in Three Groups. Difference of Opinion Existing Among Clinicians as to the Significance of a Discharge from the Nipple in the Non-lactating Breast. Results of Personal Investigation. Presentation of 3 Cases Illustrative of Each Group.**

THE cases that consult the physician because of a discharge from the nipple may generally be classed in one of three groups: Those in which the presence of a discharge is the only symptom; those in which it is associated with a cystic swelling in the region of the nipple; those in which the breast tissue proper is the seat of a single or of multiple tumors. The proper interpretation of the discharge in each instance may be a valuable aid in making the diagnosis and in determining the proper course of treatment.

If one were carefully to go over the literature one would find a wide variance of opinion regarding the significance of a discharge from the nipple in the non-lactating breast. There are those who firmly believe the physical characteristics of such a discharge, the color, consistency, odor, and amount are of real diagnostic value, while equally good men are just as firm in the opinion that they are of no importance at all. The prevailing sentiment, however, seems to be that a frank bloody discharge is almost diagnostic of a benign papilloma, a mucoid discharge characteristic of a chronic cystic mastitis, and a serous or serohemorrhagic discharge very suspicious of a malignancy.



Because of this very apparent uncertainty regarding the real value of the discharge as a means of diagnosis Dr Lewis and I have within the past year carefully reviewed some 700 cases of breast tumors at this hospital in order to determine, if possible, whether any constant relation exists between the discharge on the surface of the nipple and the underlying breast pathology. The result of this investigation may briefly be expressed as follows.

1 From a clinical standpoint the presence of a discharge from the breast is evidence of a pathologic lesion.

2 The discharge itself is described by patients in a great variety of terms, such as "watery," "milky," "cloudy," "clear," "yellowish," "greenish," "blood stained," or "bloody," and if the statements of the patients may be relied upon it often changes in character during the course of a long-continued process.

3 The amount, color, odor, and consistency depend not only upon the character of the pathologic lesion from which the discharge originates but also upon the degree to which it is altered before reaching the surface of the nipple. For example, an eroded vessel will bleed as readily whether at the tip of a benign papilloma as within a papillary carcinoma. Moreover, if this bleeding point happens to be near the nipple and the duct unobstructed, the blood will be changed little if at all as it passes to the surface of the nipple, while if the bleeding starts from a papilloma or a papillary carcinoma contained within the wall of a cyst or dilated duct lying deep in the breast, it will not only be intimately mixed with the products of cellular disintegration, but be delayed in its passage to the surface of the nipple, and consequently materially altered in appearance.

4 There is no constant relation between the type of discharge and the underlying breast pathology, but the analysis of a large series of cases furnishes sufficient data so that conclusions may be drawn which will serve as a working basis for practical diagnosis and treatment. They are as follows:

(a) When a serohemorrhagic discharge occurs and no tumor

is palpable the lesion in all probability is a small benign papilloma situated deep within the substance of the breast.

(b) When the hemorrhagic discharge is associated with a cystic swelling in the region of the nipple or areola, and can be expressed by digital pressure directly over the tumor, one is dealing, in all likelihood, with an intracanalicular papilloma

(c) If, on the other hand, the discharge at the nipple is an incidental part of the clinical picture, and the breast tissue itself is the seat of single or multiple tumors, one must always make the diagnosis upon the usual clinical signs of benignancy or malignancy, confirmed by careful microscopic section

The 3 cases we have to present will illustrate the three groups in which these cases naturally fall.

**Case I.**—A young married woman twenty-nine years of age presents herself because of a watery discharge from the nipple of the left breast which she has noticed at intervals during the past eight or nine months. There has at no time been any swelling, pain, or discomfort, and the only reason for consultation is the fear that cancer might be present. On inspection we find the normal breast of a nulliparous woman. The surface of the nipple is covered with a dry crust. No tumors can be felt anywhere in the breast, but as we come to the region of the areola and make gentle pressure between the thumb and index-finger a drop of clear watery fluid exudes from the nipple. This girl has not come prepared to be operated on today, but we advise that an exploration be made, and we would expect to find a small papilloma just beneath the nipple.

**Case II.**—A married woman of fifty years complains of a small lump in the right breast and a watery discharge from the nipple. Upon close questioning she states that the discharge is intermittent in appearance, is usually clear and watery, but at times is blood-tinged and leaves a yellowish-pink stain on the clothing. The lump, which is no bigger than a large pea and has remained so for three years, at times collapses somewhat on pressure and causes considerable fluid to come from the nipple.

On inspection of the breasts you see no difference in the external appearance, both being apparently normal. On careful palpation, however, one is able to make out a rounded lump the size of a small hazelnut just beneath the edge of the areola in its outer lower quadrant (Fig. 248, *A, B*), and upon digital press-

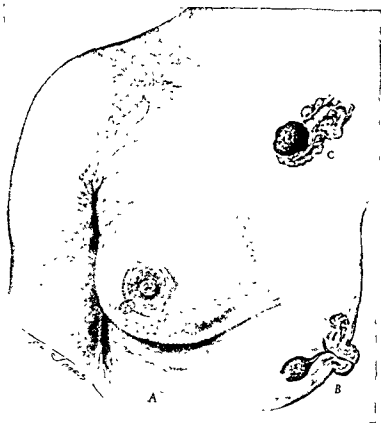


Fig. 248—Case II Intracanalicular papilloma associated with a serohemorrhagic discharge from the nipple

ure over the nodule a few drops of clear fluid are seen at the nipple. We have little if any hesitancy in making a diagnosis here of an intracanalicular papilloma, and have advised her to have it removed under local anesthesia.

The incision is a curved one along the margin of the areola

The areola skin-flap is reflected back until the nipple is inverted, and we proceed to dissect out the milk duct as it radiates toward the tumor. We have accidentally knicked the edge of the dilated duct and can see the red surface of the papilloma, so we dissect under and remove the cyst intact. After controlling bleeding at one or two points we reflect back the flap and suture it with silk. On cutting through the wall of

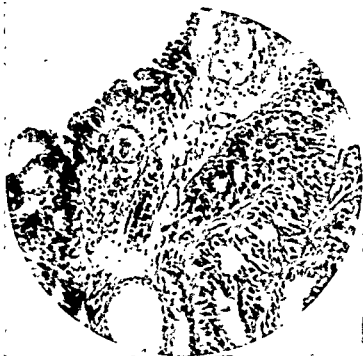

Fig. 249.—Microscopic section of intracanalicular papilloma in Case II.

this cyst I believe you can see a mulberry-sized papilloma (Fig. 248, C). (Microscopic section Fig. 249.)

Case III, representing the third group, is that of a young Italian woman of thirty-four years who came to the hospital because of tumor in the left breast, which she first noticed five years ago. Although she does not speak good English we have gathered from her information that although the tumor has increased in size of late, and has given rise to little pain or discomfort, at times she has noticed a dark ex-

the nipple. On examination we find three rather distinctly separated tumors. The largest one, occupying the area medial to the areola, is about the size and shape of a walnut, has well-defined borders, and moves freely under the skin. The second, one-third as large, although quite well defined and movable, seems to be joined with the first one by an indefinite subcutaneous bridge, while the third, which is nearly as large as the first, occupies the area beneath and lateral to the areola. Its

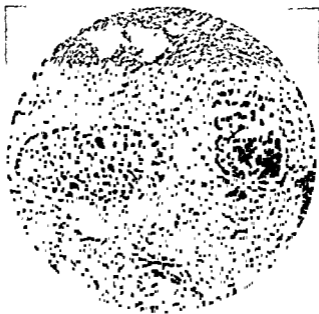


Fig. 250—Case 111 Adenocarcinoma giving rise to bloody discharge from the nipple

margins are also smooth and well defined, but there is some wrinkling of the skin as we try to lift it away from the tumor. Upon pressure here we notice a drop of thick bloody material exuding from the nipple. In making a diagnosis we must disregard the discharge from the nipple and rely upon the nature of the tumors present. The clear definition, multiplicity, free mobility, and absence of axillary glands would throw the weight of evidence toward a benign process. The only sus-

picious clew to malignancy is the slight wrinkling of the skin over one tumor and an indefinite bridge between the two others. We shall remove the breast and rely upon the microscope. The pathologist reports adenocarcinoma (Fig. 250), and we are impressed by the striking example of the necessity of relying in cases of this type not at all upon the kind of discharge, but upon the gross and microscopic appearance of the tumor.



## CLINIC OF DR. HUGH N. MACKECHNIE

### POST-GRADUATE HOSPITAL

#### METASTATIC HYPERNEPHROMA OF THE FEMUR PRODUCING SPONTANEOUS FRACTURE

Spontaneous Fracture of the Femur in a Patient Who Had a Nephrectomy for Hypernephroma. Differential Diagnosis, Modes of Transmission, Prognosis, Treatment.

Mr. J. O. K., aged fifty-four, complains of an inability to use the right leg because of what appears to be a fracture in the thigh which prevents proper control of limb. He has no pain except on movement, and then it is very mild.

During the past six months he has been taking treatment for pains in the right thigh which have been diagnosed as rheumatism. At times they appeared somewhat improved, but this was only temporary. Recently he came under the care of Dr. Mader. He complained at that time of a dull aching pain, deeply placed in the upper part of the thigh, with a point of greatest tenderness on the lateral surface about the junction of the middle and upper third. The pain was equally bad, day or night, walking or sitting.

In the course of examination, while testing muscle and joint conditions with the limb raised from the floor, coincident with flexion of the ankle, the patient felt "something snap and give way in the thigh" and he lost control of the limb.

He was removed to the hospital and referred to my service.

**History.**—This patient has a history of unusually good health. He had some children's diseases, but does not remember which ones. He gives a history of chancre and neisserian infection at the age of twenty, both of which have long since been cured. He had rheumatism at about thirty years of age. In recent years he has been exceedingly well except for a time four years





**Diagnosis.**—Here we are confronted with the evidences of a pathologic and clinical fracture due to a tumor growing within the medulla of the femur. It is evidently caused by one of the tumors that do not produce a swelling of the bone, a formation of new bone, or a reaction in the surrounding tissues. There is here a destruction of bone by a tumor developing within the medullary cavity and causing an absorption of the cortex.



Fig. 251—Skiagraph of fracture showing deformity of femur, the uniform bone erosion, the absence of new bone formation, and of reaction in surrounding tissue except as of recent hemorrhage

The history of a nephrectomy for a hypernephroma four years ago, the persistent pain not yielding to treatment, the irregular ends of the tumor in the medulla, the absence of evidence of new bone formation in or around the tumor, the lack of reaction or invasion of the surrounding tissue by the tumor, the absence of swelling of bone, and the location in the upper third of the femur would suggest a probable metastatic hyper-

nephroma It is at this point that these metastases occur most frequently. Carceau in 35 bone cases reports the following locations: The femur, 7; vertebræ, 7; ribs, 6, clavicle, 2; skull, 5; pelvis, 2; humerus, 2; scapula, 1, jaw, 1; tibia, 1; metacarpal, 1.

Osteitis fibrosa cystica produces a condition much like that described above. There is no primary focus, the tumor mass is well outlined in the skiagraph, with some evidence of a limiting membrane

The osteogenetic sclerosing sarcoma produces a rapid destruction of the bone with new irregular bone formation, breaking through the periosteum, and invasion of the surrounding tissues

Primary telangiectatic sarcoma with its infiltration of bone together with some regeneration shows bony spicules within the growth There is also a spindle-like enlargement of the whole bone, with a thin shell of new bone formed beneath the periosteum.

**Prognosis.**—Hypernephroma does not warrant a good prognosis The immediate mortality after operation is above 25 per cent. More than 6 per cent. died within the first year. The average duration of life is about two and one-half years, the patients dying from metastases. One patient has lived for ten years. Metastases occur, according to Carceau, as follows: Bone, 35; lungs, 21; liver, 8; lymph-glands, 11. The appearance of secondary growths adds greatly to the seriousness of the prognosis for the individual case. Albrecht reports a case alive and well two years and seven months after removal of metastases in the scapula. The kidney had been removed four years previously. In 16 nephrectomies 4 were alive after four years, and 3 of these had developed metastases.

**Modes of Transmission.**—The question of the mode of spread of these metastases is quite unsettled, whether through the lymph channels or through the blood-vessels. There are cases reported of lymphatic gland involvement in the abdomen and inguinal regions, but none in the more distant glands. There is also reported by Keyser and Foulds the presence of hypernephroma cells along the renal vein in a case carefully studied by them. The anatomic study of the bones, according to Piney,

demonstrates the presence of lymphatics in the periosteum, with some entering the cortex, but fails to show any in the endosteum and medulla. He further shows the presence of small groups of malignant cells in the endothelial lined vessels in the medulla. It would seem from the cases cited together with the anatomic studies that the preponderance of evidence favored transmission through the blood-stream.

**Treatment.**—Is this a benign tumor or is it a malignant one? Should it receive the most conservative treatment of replacement of the fracture with extension and rest, radium and x-ray therapy, or should it be operated? If operated, should it be cureted and cauterized, or should local bone be excised with shortening of the limb, or should disarticulation at the hip-joint be done.

Bloodgood thinks that the cases of benign cysts do as well with ultraconservative treatment as with operation. The breaking of the bone and cyst capsule stops the development of the cyst and appears to stimulate the growth of new bone. On the other hand, removal of the cyst contents and correction of the deformity are good surgery. The use of a bone transplant is justifiable where the bone ends are very friable and cannot be held in position, and where shortening will occur in spite of extension because of the longer period required for union without it.

The malignant cases are more of a problem. They are always secondary, and the question of other metastases arises. Unfortunately few autopsies have been comprehensively performed and the frequency of multiple metastases is not known. It appears improbable that a single metastasis would be the rule in blood-borne conditions.

The duration of the disease subsequent to the primary growth, the anemia, skiagraphs of other bones, together with the general physical condition of the patient will aid in deciding on the presence or absence of other metastases and the line of treatment.

It would seem, however, that every case is entitled to an exploratory operation for the purpose of determining definitely the tumor present.

This latter procedure we will carry out for this man.

**Operation.**—We will make our incision on the outer and anterior surface of the thigh, directly opposite the point of deformity. The skin and muscles are cut through to the bone, and here we find much clotted blood, which we evacuate. We retract the soft tissues and come to the tumor mass, part of which is torn loose and part is in each end of the bone. This we remove *en masse* with facility, as it is not attached to the bone, and at once will have it sectioned. Grossly it has no capsule, is grayish in color, firm in consistency, has very few small vessels, cuts with slight resistance to the knife. It has much the gross characteristics of hypernephroma. A cyst has a capsule filled with a grumous gelatinous-like mass which cuts readily and flows out slowly.

The frozen section indicates that this is a hypernephroma with some tubule formation much resembling the tubules of the kidney.

We will now curet this bone to remove all the tumor, together with much of the neighboring tissues, and close it up with the bones properly replaced. I find that they will not hold in proper alignment because of the thin layer of compact bone with irregular edges. I therefore use a sliding bone-graft from the lower fragment and suture it in place with kangaroo-tendon.

Now we will put him in a half-body case involving this leg as far down as the knee and will return him to bed. His condition is not the best and, remembering that he has only one kidney and a heart involvement, we must lose no time.

**Further Treatment.**—The question of deep therapy comes up at this time, and with it we are placed on the horns of a dilemma. Deep therapy of sufficient strength to destroy cancer cells will have a retarding effect on the cells of new forming callus and bone. On the other hand, light doses of therapy of a stimulating nature to increase the rapidity of growth of fibrous tissue and of bone will have a like effect on any malignant cells that are not removed. I will advise the heavy dosage because the killing of the tumor cell is of prime importance. When this is accomplished a non-union, if such should occur, can be treated as a separate entity. On the other hand, a union will be of no value provided the malignancy remained.

**Pathologic Report.**—The tumor is an oval-shaped mass 3 inches long by  $1\frac{1}{4}$  inches diameter. It is firm and resistant, grayish in color, and cuts readily. It has no capsule, but appears to be well limited in development.

The microscopic sections show glandular type of formation much resembling that of the convoluted tubules of the kidney (Figs. 252, 253). There are, however, areas in which this tubular formation is less distinctly formed and even where broad sheets of cells are seen.

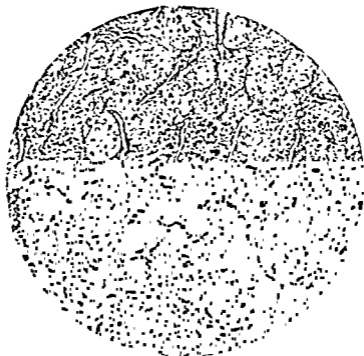

Fig. 252 —Section of tumor mass, low power (75 diam.), showing the tubular arrangement of cells much resembling that of the kidney.

**Later Report.**—The patient evidenced considerable reaction from the operation. There was some shock lasting about four hours. Albumin and casts appeared in the urine in fair quantity for several days. The heart has not further dilated and the sounds were as before the operation.

He has had one series of deep x-ray therapy. The skin is quite bronzed and sensitive. The wound has healed by primary union, and even in the cast there appears to be less movement

at the fracture and more at the hip-joint. A skiagraph shows well-developing callus and some new bone formation

**Points of Interest.**—The history of dull pain for which no cause can be found, which does not respond to treatment, is very suggestive of a medullary bone tumor. There are few nerves in the medulla and cancellous bone, and so pain is mild. In the cortex they are absent, while in the periosteum they are well developed. As the tumor develops and the compact bone



Fig. 253.—High power (275 diam) of portion of Fig. 252. Note the large clear cells with large nuclei entering into the formation of the tubules

is eroded the periosteum becomes involved and the pain is more pronounced.

The absence of swelling of the limb in the region of the pain preceding the time of fracture suggests a metastatic or a cystic rather than an osteogenetic tumor

The need of early skiagraphs in those cases of persistent dull pain as an adjunct in making a correct diagnosis is important.

## CLINIC OF DR. LEROY H. SLOAN

ILLINOIS CENTRAL HOSPITAL

---

### IDIOPATHIC DILATATION OF THE ESOPHAGUS

Patient Presenting Symptoms of Dilatation of the Esophagus. Examination—Physical and Fluoroscopic. Conditions Responsible for Difficulty in Swallowing. Operation. Death of Patient. Autopsy Report.

THE patient whom I desire to present to you this afternoon comes to the hospital because of "difficulty in swallowing and a feeling of fulness and pressure in the epigastrium." While this is the complaint, we find, on closer analysis, there is no difficulty in the actual performance of the act of swallowing, but rather that food seems to lodge near the cardiac orifice producing irregular regurgitation, a bad odor, bothersome belching after swallowing and even, it would seem, during swallowing, and a more or less vague continuous discomfort. This condition was first noted two years ago, has not kept the patient from work until now, has become pronounced during the last two weeks, and is associated with marked loss in weight. Up to about one month ago the patient was conscious of the exact time at which the discomfort would disappear in the epigastrium and there would be a *left upper abdominal distention*.

Proceeding with the examination, we find an adult male of placid temperament, weak, and tired. Scalp closely approximated to skull, eyes sunken, malar bones prominent, neck slim, chest markings accentuated, abdomen scaphoid, extremities emaciated—in brief, presenting the picture of rapid loss of weight. The pupils are equal, react to light and accommodation, no nystagmus, no ocular paresis, no mastoid tenderness,



hearing normal, usual cervical adenopathy, *no sentinel gland, no tumor of neck, no bulging on either side at the sternoclavicular region or thereabouts, no pharyngeal tumor mass, and no epiglottic swelling.* The mucous membranes do not suggest a recent severe hemorrhage or anemia due to malignant toxemia. Litten's sign reduced on right, inspection and percussion expansion also. There is hyperresonance over the upper right lobe anteriorly with relative dullness shading into flatness over the right lower. We seem to have an increased liver flatness both anteriorly and posteriorly. Breath sounds are fairly well transmitted over the upper right chest, but reduced or absent over the lower right. A few crackles are heard along the vertebral border right interscapular region. I can find no active peripheral pulmonary pathology in the left lung. The heart is normal in size and position. There are no organic or functional alterations. No hippocratic succussion is elicited over the right chest. There is upper bilateral abdominal tenderness without mass. Reflexes are all normal. The patellars are lively.

The blood Wassermann is negative, the spinal fluid entirely normal, the urine shows a trace of acetone. Aspiration of stomach is unsuccessful. We obtain food material from several meals back. There is no free hydrochloric acid.

With such a history and findings our attention is attracted toward the esophagus. We will now fluoroscope the patient to demonstrate to you a most unusual esophagus. Note that over the right chest there is a haziness which becomes more pronounced as we go toward the diaphragm. This haziness is continuous with a dependent, opaque rounded mass. This is not the haziness of fluid, or thickened pleura, or of consolidation. The heart is normal in size and position. There is no saccular bulging or diffuse dilatation of the aortic arch. The left diaphragm moves freely. Now watch the obscured right costophrenic angle. We see the diaphragm peel away from the chest wall, and as it does are able to see that the rounded opaque mass is *supradiaphragmatic*. We will now give the patient 250 c.c. of thick barium mixture, turning him slightly toward the left to more clearly visualize the course of the esophagus and its relation to the hazi-

ness noted previously, which extends up almost to the fourth rib. The barium flows in readily, but almost immediately drops into a sac continuous with the rounded mass. This sac is a part of the esophagus. The patient has taken all of the barium. He swallows with ease. This produces considerable belching. As we give him more of the mixture the esophageal shadow becomes larger. A fluid level is rising gradually, which maintains the horizontal much like a hydropneumothorax. If you look closely you will see the barium slipping along the upper border of the sac and dropping down the posterior wall, giving the appearance of a torn lace curtain. We will pass a soft stomach-tube. It goes down readily, strikes bottom, coils up, and, hugging the right esophageal wall, pushes it out to the chest wall. We have the entire length of tube beyond the tooth line. We will now aspirate. See the right wall flop back as we do so. Most of the material is now removed. Our junior intern tells me that he has aspirated 60 ounces from this esophagus. He thinks it will hold more without difficulty. We will now pump in some air. See the wall push out to the right. Percussing the chest, we now find a generalized hyperresonance. Breath sounds and voice transmission are greatly reduced to absent.

You have seen a most unusual esophagus containing at least 1800 c.c. Quite by coincidence we have in the hospital another enormous esophagus, though not so large as this. Rare pathology has a habit of coming in pairs or threes.

What conditions bring a patient to you complaining of difficulty in swallowing? Of the more common we have

*Foreign Bodies.*—Fish-bones, buttons, and the like. We have no history of such.

*Corrosive Trauma.*—Here we are dependent upon a history of an acute esophagitis usually due to lye or acid followed by ulcer formation, scar tissue contraction, and chronic difficulty. We can elicit no history even suggestive of such in this patient.

*Mural Tumors.*—Is this a carcinoma? No. A carcinoma producing such a proximal dilatation cannot be more than imagined. This began two years ago. Esophageal carcinoma of this duration would show a characteristic picture. Malignancy

produces encroachment upon the canal, destruction of tissue, ulceration, and a ragged, moth-eaten, irregular *x*-ray picture. It is not confined to one circumscribed area when we see it. With more frequent esophagoscopy it is to be hoped that such will be the case. *Lues* might give a limited stricture, though the usual picture closely resembles carcinoma.

*Diverticulum*.—This is a localized bulging usually seen in the upper esophagus at about the sternal junction. In our



Fig. 254—Esophagus, stomach, duodenum, and right lung, viewed from anterior surface

patient we have a stretching of the entire right wall almost from the beginning. It cannot be classed as a diverticulum.

*Extra-esophageal Pressure*—From our fluoroscopic examination we are permitted at once to dismiss aneurysm, tuberculosis, mediastinal adenitis, and lymphogranulomatosis.

By exclusion we arrive at the so-called idiopathic dilatation or cardiospasm. In early spastic cases we have a hanging of barium in the canal. Later the irrigating jar appearance. Later the funnel bottom and upper dilatation. Here we have an eccentric dilatation. Is it not possible that we have a cardiac

stenosis similar to the hypertrophic pyloric stenosis? It is. This condition has existed for years—spasm was present early, now obstruction.

How should we treat this patient were the condition early? By washing the esophagus twice daily with warm bicarbonate water, feeding in small amounts at frequent intervals—milk, broth, orange juice with lactose, eggnog, and the like. Passage of a soft stomach-tube will relieve a certain percentage early. Dilatation with one of the various dilators will suffice for some.

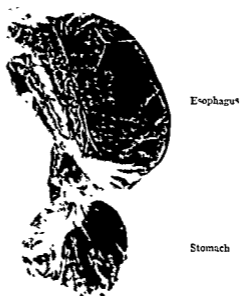


Fig 255.—Esophagus, stomach, and first portion of duodenum, viewed from posterior surface.

It may be necessary to give the patient a thread and, when fixed, dilate, using one of the more recent types of dilators with the thread as a guide. A solid bougie may be passed by aid of the fluoroscope. Tincture of belladonna, atropin, hyoscyamus, and benzyl benzoate may be used as adjuncts to the above treatment. Dilatation under view of the eye, using the esophagoscope, is favored by many. In our particular case I believe that gastrostomy is indicated. This patient is in serious condition. It will be done under local anesthesia. At this point may I call

your attention to the recent splendid symposium published in these clinics on esophageal conditions by Jackson and his co-workers in Philadelphia. Especially may I suggest the article on Retrograde Esophagoscopy by Tucker as related to the case in hand.

*Further Note.*—Gastrostomy was done; the patient did not respond. Attempted passage of tube through duodenum met



Fig 256—Lower portion of esophageal sac filled with barium. Stomach-tube in the esophagus which is distended to about three-fourths size

with no success. The patient died shortly, and at autopsy showed the following essential findings as noted by Dr. H. Gideon Wells: Right pleural cavity largely filled posteriorly by a sac which forces the lung forward. The upper margin of this sac is at the first interspace posteriorly and the sac extends to the diaphragm. There are no adhesions in the right pleural cavity. (This is interesting as showing the non-inflammatory

character of the pathology.) The mass consists of an enormously dilated esophagus which is also slightly dilated in the cervical portion. At the lower cervical region the dilatation is 12 to 15 cm. in circumference. The intrathoracic portion is 19 cm. in diameter. There are many large old blood-clots in the lumen. There is no compression of the trachea or aorta. The wall of the esophagus is of uniform thickness. Large veins course over



Fig. 257.—Esophagus partially filled with barium mixture.

the external surface. The cardiac orifice admits the gloved finger readily, but when the sac is full the finger is compressed tightly by a band formed by a kinking of the orifice.

For the earlier literature may I refer you to the articles of Tyson, Martin and Evans,<sup>1</sup> Sippy,<sup>2</sup> and Kinnicutt,<sup>3</sup> and the discussion thereon. Kinnicutt reports a case with a capacity of 1800 c.c.

We have progressed little in determining the etiologic factors concerned in dilatation of the esophagus. Brooks<sup>4</sup> calls attention to the conception of Zenker and Von Ziemssen of an enfeebled musculature dependent upon unrecognized disease. He also refers to Oettinger and Gaballere's mego-esophagus and the comparison of it to Hirschsprung's disease. Meltzer<sup>5</sup> refers to cases of stenosis of the cardia due, he believed, to



Fig 258 --Esophagus filled to three-fourths capacity with barium mixture.

purely functional factors. Jackson and Spencer<sup>6</sup> prefer the term "phrenospasm" and call attention to the muscle bundles connecting esophagus and crura of diaphragm. They report a case with a capacity of 1500 c c. More recently Smici and Giurea<sup>7</sup> present a megaloesophagus, and express the view that it is probably a congenital tissue malformation diminishing the resistance of the wall to interior pressure and permitting dilatation. In our case we assume a long symptomless period with gradual dila-

tation due mainly to stretching of the right wall, followed by cardiospasm and terminal mechanical obstruction.

#### BIBLIOGRAPHY

1. Tyson, Martin, and Evans: Transactions of the Association of American Physicians, vol xiv, 1904
2. Sippy, Bertram: *Ibid.*
3. Kinnicutt, Francis P.: *Ibid.*
- 4 Brooks, Harlow: Practice of Medicine, Tice, vol vii
5. Meltzer, S J.: Berl. klin. Wochenschrift, 1888, No. 8
6. Jackson and Spencer: Nelson Loose Leaf Living Medicine
7. Simici, D , and Giurea, G.: Archives des Maladies de l'Appareil digestif, November, 1923, xiii, No. 9, p. 854.





### BILATERAL CHARCOT KNEES

Etiology, Pathology, Diagnosis, and Treatment of Neuro-pathic Arthropathies. Presentation of a Patient with Charcot Knees.

BILATERAL Charcot knees are of sufficient rarity to justify recording a typical case, and will serve to introduce the subject of Charcot or neuropathic arthropathies.

**Etiology.**—Neuropathic arthropathies are found in tabes dorsalis, syringomyelia, compression and destruction of the spinal cord, severance of nerves, pernicious anemia, peripheral neuritis, etc. In tabes dorsalis the joints of the lower extremity are usually affected; in syringomyelia, usually those of the upper extremity.

The two factors involved are, first, the neurotrophic, and second, the infectious element

The neurotrophic factor consists of the lack of normal trophic impulses reaching the joint. The infectious element means the presence of a local infective agent or its by-products in the joint.

**Pathology.**—The pathology consists of local and general findings.

**Local.**—Locally there is found extensive destruction of articular and periarticular structures, viz., articular cartilage, semilunar fibrocartilages, and crucial ligaments.

The lateral ligaments and capsule undergo stretching and weakening rather than destruction.

There is bone destruction with loosening of bone-plaques.

There may be bone proliferation as seen in the hypertrophic type, which process appears to progress simultaneously with the destruction

*General*—The general findings are those of tabes dorsalis, especially cerebrospinal degeneration

*Symptoms.—General.*—Eyes: Argyll Robertson pupil, with absence of reaction to light

Disturbance of reflexes Occasionally exaggerated at first, but absent later Lightning pains, especially in the legs.

Romberg sign: Instability while eyes are closed. Other motor disturbances, such as ataxic gait, involuntary movements, and palsies

*Gastric crises, disturbances of visual, auditory, and visceral apparatus*

Sensory disturbances, *i. e.*, analgesia, "tabetic cuirass," hyperalgesia, and delayed transmission of sensation.

Wassermann test on blood and spinal fluid.

Spinal fluid examination, cytologic, chemical, and gold chloride test of Lange.

Therapeutic test.

*Local.*—Swelling, absence of pain, disalignment, abnormal mobility, crepitus usually coarse, absence of sensitiveness.

*x-Ray findings.* The most characteristic finding is the extensive destruction of bone, but, in addition, proliferation of bone occurs in the hypertrophic type. Loose bodies are very common. There is a noticeable absence of atrophy due to the fact that this type of joint is not painful, therefore it is used. Tissue examination reveals the characteristic microscopic picture and *Spirochæta pallida* (by dark-field illumination).

*Diagnosis.*—The direct diagnosis is based on the history and examination

*Differential*—The differential diagnosis lies between tuberculosis, arthritis, synovitis, fracture, dislocation, malignancy, and septic infection (Table I, pages 786, 787).

Tuberculosis manifests itself by limitation of motion, muscle spasm, pain, sensitiveness, bone atrophy, destruction, but comparatively rarely production. The only positive tests are find-

ing tubercle bacilli in the fluid or pus, in microscopic sections of bone or synovia, or by guinea-pig inoculation test. Malignancy is diagnosed by history of a primary tumor, especially in the breast, prostate, thyroid, adrenal or gastro-intestinal tract, and by roentgenogram.

Fracture and dislocation are determined by roentgenogram.

Septic infection reveals swelling, redness, severe pain, and local fever. Aspiration is conclusive.

Synovitis is shown by swelling, pain, tenderness and thickening of synovia on palpation.

Roentgenogram is negative.

Arthritis is evidenced in various ways, depending upon the type and duration. In general, there is limited motion, pain, often multiple joint involvement, and the roentgenogram reveals atrophy or hypertrophy, or both.

Higgins gives the following classification of luetic arthropathies:

Congenital syphilitic lesions	{ Osteochondritis syphilitica. Simple synovial effusion Arthropathie deformante
Secondary syphilitic lesions	{ Arthralgia Acute synovitis. Hydrarthrosis Bursopathy of Verneuil.
Late syphilitic lesions	{ Bursopathy of Verneuil Tumeurs blanches syphilitiques Acute or chronic synovitis. Gummatous osteo-arthritis Charcot's joint.

**Prognosis.**—The prognosis as to life is good. The chances of obtaining a stable weight-bearing leg by means of apparatus are very good. In regard to operative improvement there have been a few examples of successful arthrodesis or joint resection. Lewin was successful in 1 case of arthrodesis at the Cook County Hospital. The course is long.

**Treatment.**—The treatment consists of stabilization and anti-luetic medication. Stabilization consists of the application of braces or plaster-of-Paris casts or operation. The best type of

TABLE I

	Charcot	Tuberculosis	Syphilis	Chronic arthritis	Malignancy	Septic infection	Bursitis	Fracture	Dislocation
Duration	Short	Long	Acute in course	Chronic	Long	Short	Long or short	Short	Short
History	Moderately insidious	Gradual	Sudden or gradual	Gradual	Orbital	Subtle	Sudden or gradual	Subtle	Subtle
Onset	Usually	Not severe	+	+ or -	+ or -	+ or -	Repeated - joint	+	+
Physical examination, other important findings	Ex. effusion of joint decreased. Motion and axillary disturbance. Glands. Rosenberg. Argyll Robertson pupil Loss of reflexes, etc.	Other form of labor edema Lungs. Glands. Bowley. Bones	0	Other form of infection Mela bone disturbances	History of py- emia Briant, myr Cachectia, etc.	May have other feet. Tendis, etc.	Repeated - joint negativ	Negative	Negative
Malignant	Abnormally free	Limited	Limited	Limited	Limited	Absent	Limited	Limited	Limited
Much swollen	-	++	+	-	-	+	0	+	+
Red.	Strepococci, staph	Limp	Limp	Limp	Limp	Doesn't walk.	Limp	Usually doesn't walk when very slight fracture	Doesn't walk.
Altitude	Not characteristic	To protect joint.	Of protection.	Of protection.	Of protection.	Excess	Excess	Excess	Not characteristic
Pain	Absent	+	++	Dull	++	++	++	+	+
Night time	Absent	++ in relation	+	0	Night pain severe	Night pain	0	0	0
Swelling	+++	+	+	+	++	++	Localized to bursa	+	+ or -
Atrophy	Not marked	++	0	++	++	+	0	0	0
Deformity	+++	Due to gravity bone destruction good muscle con- tracture	Of protection	+	+	Phoson.	+ or -	+ or -	+
Temperature and its variations.	Absent.	+	++	Not marked.	++	+++	++	+	+
Local temperature	Absent.	+	++	0	+ or -	++	++	0	0
Joint tension	Increased.	Increased due to swelling.	Increased.	Increased slightly	+	Increased.	Localized to bursa.	+ or -	+ or -

General symptoms.	Of cerebrospinal fluid.	Malign, aneurhaxia, afternoon temperature.	D	.	Of malignancy	+	0	Not necessary	Not necessary
Atrophy	0	++		+	++			0	0
Destruction	+++	+		+	+			0	0
Production.	If hypertrophic type	Usual.	Negative	+ or -	Usual.	Negative		0	0
Invasion of joint	++	++		-	Unusual.			+	+
Other characters (urate, debris, etc)	Debris. Loose bodies	Hardness of joint space		-	Invasion of soft parts				
Abscess or sinus.	0	Common	0	0	0	+ or -		0	0
Amyloidosis.	0	Occasionally	0	0	0	0		0	0
Paralysis	Pain of tubes =	Occasionally	0	0	0	0		0	0
Micturitus.	Usually other joints, hip, ankle, spine	Frequent	0	May have other joints affected.	+	+ or -		0	0
Energy and macrocy	0	Tuberculous shows bacilli, etc., in bone or synovia	Of synovial inflammation	0	Of malignancy			Increase for drainage	
Bacteriologic examination of fluid.	0	Shows tuberculous bacilli frequently	May show pyogenic organism	0	0	Pyogenic organisms.		0	
Guinea-pig inoculation.	0	+	Not necessary	0	0	Pyogenic organisms.		0	
Tuberculin tests	-	+	0	0	-	0		0	
Blood tests, spinal fluid examination.	Wassermann + usually above cerebrospinal fluid, cells, globulins and Lange tests. Wassermann.	0	0	0	-	0		0	
Therapeutic test.	For lusa.	For tuberculous.	Rest.	Rest, immobilization, later physiotherapy and diathermy.	-			0	

braces are the walking caliper knee-splint or the Jones knee-cage, which allows flexion and extension, but no lateral or rotatory movements. Operation consists of arthrodesis or removal of remaining cartilage, or joint resection and immobilization. Antiluetic medication is salvarsan, tryparsamid, mercury, and iodids. Recently Moore Robinson and Keidel<sup>1</sup> recommended tryparsamid in cerebrospinal lues.

The patient whom we wish to present this morning is Mr. V. R., age thirty-three years, who entered the hospital July 15, 1923. The history taken at that time is as follows:

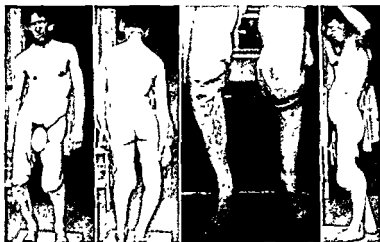

Fig. 259

Fig. 260

Fig. 261

Fig. 262

Figs. 259-262—Bilateral Charcot knees (Authors' case)

*Present Complaint.*—Weakness and swelling of both knees. Duration of trouble in right knee four years, in left two years. Shortness of left leg, duration five to six months. Knees bow outward and are “too loose.”

*Present Illness—Onset and Course.* Fifteen years ago he was playing football and had both knees “put out of joint.” He was in bed several weeks following this, but never had any more trouble with his knees until four years ago. His right knee began to swell about four years ago. It kept getting progressively larger for about a week, and then he went to a doctor,

<sup>1</sup> Jour Amer Med Assoc, February 16, 1924, vol 82, p. 528.

who withdrew a large amount of fluid from the joint. He rested for several days and then started to work again. Intermittently the knee would swell slightly, and then would become of normal size after several days' rest. Two years ago the left knee began to enlarge. This enlarged more rapidly than the right had. Within a few months he noticed there seemed to be a slight bowing outward of left knee. He had a brace made to hold the knee in position. At no time has patient had any pain. He has been working almost every day since the onset. Five months ago he noticed the left leg started to grow shorter than the right. This has not been increased much, but the knee has been getting continually larger. The knee is larger when he puts weight on it than when he is resting. He can feel crepitus on motion in both knees. He believes he can feel small pieces of bone in the joints.

Patient had a urethral infection seventeen years ago. He denies ever having had a chancre. He has never had an eruption over the body. He says several blood tests have been taken, but they have all been negative.

*Past History.*—Negative except for accident referred to above.

*Physical Examination.*—*General.*—The patient is a poorly developed white male about thirty-three years old. Temperature and pulse-rate normal.

*Head and Neck:* Pupils are slightly irregular and unequal in size. The left larger than the right. The left is absolutely fixed to light and the right nearly so.

*Nose, ears:* Grossly normal.

*Teeth* in fair condition.

*Tonsils* small. The mucous membrane of the pharynx is slightly injected.

*Neck:* No goiter, no adenopathy.

*Chest:* Rather slender, but symmetric. Many coarse moist râles are heard over the right chest posteriorly, especially over upper and middle lobes. Vocal and tactile fremitus are each increased here a little. No change in percussion note can be made out.



Heart: No cardiac hypertrophy. Tones are pure, clear, and rhythmic.

Abdomen: No masses, tenderness, or rigidity. Liver, spleen, and kidneys not palpable.

Extremities: The right knee-joint is flail. The leg can be moved in any direction. Lateral and rotary movements at the knee are very pronounced. They are not accompanied by pain.

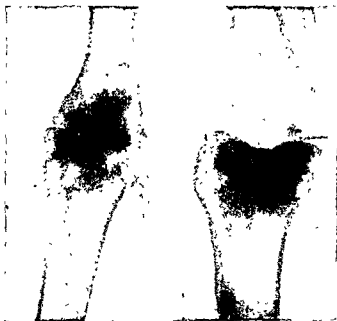

Fig 263

Fig 264

Figs 263, 264—Bilateral Charcot knee. Right knee, showing obliteration of joint space, destruction and proliferation of bone.

The joint is enormously enlarged to about the size of a child's head. There are many bony nodules to be felt and much crepitus on motion of the joint. There is apparently no functioning of the joint capsule, crucial or lateral ligaments. There is a similar condition of the other knee, but it is less marked.

*Neurologic Examination*—Babinski sign is negative. Knee-jerks cannot be obtained. Triceps reflex is normal. Sensation is good except over middle third of each leg he cannot distin-

guish the head from the point of a pin. There is no other paresthesia or paralysis.

*Laboratory Findings.*—Blood examination showed 9650 leucocytes; 96 per cent. hemoglobin, Wassermann test positive—10 per cent. in the cholesterinized antigen; negative with the acetone-insoluble antigen.

Urine showed a very faint trace of albumin and many bacteria, but was otherwise negative.



Fig. 265.



Fig. 266.

Figs. 265, 266.—Bilateral Charcot knee. Left knee, showing dislocation.

Spinal fluid examination showed the Wassermann test clearly negative; Ross-Jones negative and Pandy positive; 4 cells per cubic millimeter.

Roentgen-ray examination by Dr. E. L. Jenkinson revealed the following:

"The bones of the right knee seem somewhat sclerosed. There is a great deal of detritus extending outward into the soft tissues, especially along the anterior and posterior surfaces. The articular surfaces of the femur show some involvement, and there is a moderate amount of irregularity. The superior



Fig 267      Fig 268

Figs 267, 268 —Same patient wearing lock-joint braces



Fig 269 —Charcot knee Treated at Northwestern University Medical School Dispensary by Dr Lewin



Fig 270 —Charcot knee Treated at Northwestern University Medical School Dispensary by Dr Lewin. (Same as Fig 269)



Fig 271 —Charcot knee. Treated at Northwestern University Medical School Dispensary by Dr Lewin (Same as Fig. 269)

surface of the tibia is irregular, thickened, and the anterior surface shows a small area of bone rarefaction. The patella is irregular and there is considerable new bone formation along the posterior surface. The patella is displaced upward and forward. There is a dislocation of the bones of the left knee. The femur is displaced inward, forward, and downward. There is a large concavity involving the articular surface of the femur, which may be due to pressure following a false joint or to a




Fig 272.—Charcot joint, both ankles. Pathologic fracture of left tibial not recognized for six weeks. (Patient of Dr. John L. Porter, who had another patient with both ankles affected.)

neuropathic condition. The external condyle of the femur is practically absent. A portion of the internal condyle is still present. The articular surface of the tibia is practically destroyed, and the proximal end of the bone is eburnated. There is considerable detritus extending outward into the soft tissues and the patella is displaced upward and forward.

“*Summary.*—The pathology has the physical characteristics of a neuropathic lesion, such as a Charcot or a syringomyelia.

It is, however, rather unusual to see both knees involved in a Charcot joint."

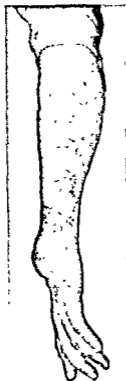

Fig 273—A case of Charcot wrist due to syringomyelia Patient of Dr Archibald Church



Fig 274—A case of Charcot wrist due to syringomyelia Patient of Dr. Archibald Church (Same as Fig. 273 )

**Treatment.**—The patient was put on antiluetic medication. Plaster-of-Paris casts were applied to both legs and replaced later by the walking caliper knee splint.

## CLINIC OF DR. FREDERICK CHRISTOPHER

EVANSTON HOSPITAL

### SEVERE SPREADING CARBUNCULAR INFECTION OF CHEST WALL FOLLOWING RIB RESECTION UNDER LOCAL ANESTHESIA

**Lobar Pneumonia—Empyema—Rib Resection Under Local Anesthesia—Carbuncular Infection Starting at Operative Wound and Spreading Very Widely Peripherally—Patient Suffering from Excruciating Pain and Emaciation—Delirious at Times—Numerous Methods of Treatment Tried Unsuccessfully—Methods Successfully Employed by the Author, who Acquired the Case on the Eighty-third Day Postoperative.**

THIS patient, Mr. F. R. B., aged sixty-four, a retired business man, was admitted to the Evanston Hospital on March 21, 1923 with the following history:

Shortly after Christmas, 1922, the patient sustained a severe blow on the left side of the chest while boarding a street car. Since that time there gradually developed a dull ache, shortness of breath, and a cough. About February 15, 1923 Dr. Stephen V. Balderston was called. He made a diagnosis of lobar pneumonia and confined the patient to bed. Shortly before admission to the hospital aspirations of the chest obtained pus, and at this time the patient also coughed up large quantities of thick, yellowish, foul-smelling pus. A diagnosis of empyema was made, and the patient sent to the hospital. On the day of admission a rib resection was performed by an attending surgeon under local anesthesia. Thick greenish-yellow, ill-smelling pus was evacuated, and a rubber drainage-tube was inserted. Direct smear of the pus from the pleural cavity was

reported; Gram-positive cocci in chains; long slender Gram-negative bacilli. The anaerobic culture revealed small round Gram-positive cocci in chains, resembling streptococci and Gram-negative bacilli. There was a very slow growth of hemolytic streptococci on aerobic media.

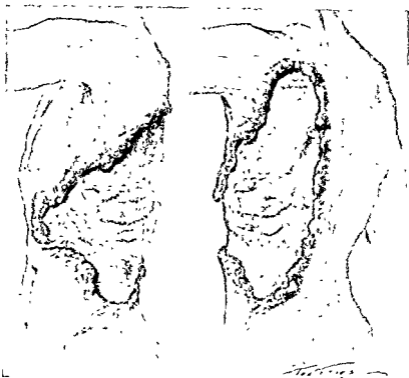

Fig 275 —Condition of patient upon eighty-third day at the time the author took charge of the surgical care. The area marked X is a plateau of new skin in the center of which is the scar of the old rib resection which had been done under local anesthesia. The borders of the ulcer have all the characteristics of the carbuncular swelling. They are necrotic, purulent, and exquisitely painful. The floor of the ulcer is composed of red, healthy granular tissue.

The patient was quite comfortable immediately after the operation, but beginning the third day postoperative he began to have a new soreness about the wound. On the sixth day the patient complained of a great deal of pain around the wound.

The areas about the stitches were very red. Hot boric dressings were applied to the wound. On the tenth day the stitches were removed. The patient became very restless and complained of considerable pain. On the thirteenth day a diagnosis of "beginning boil" was made.

The "boil" enlarged rapidly despite the hot boric dressings and large pieces of necrotic tissue were removed from it. On




Fig 276—Arrangement under which "dressings" were carried out. The patient, having been given a hypodermic of morphin, is anesthetized in his bed. Necrotic and purulent border of the carbuncular infection was débrided in the manner shown. The cut surface left after each stroke of the scalpel was immediately seared over by actual cautery. The chief purpose of this procedure was to control hemorrhage.

the twenty-first day 1:5000 bichlorid of mercury dressings were applied to the boil for one-hour intervals. On the twenty-second day Carrel-Dakin treatment was instituted and the bichlorid applications were used occasionally. The patient became very much depressed, and his pain was such that he did not want to be touched or moved even to change the bed linen or give him his bath. Codein, aspirin, and adalin were adminis-



tered irregularly. Occasionally the Dakin dressings were followed by hot boric dressings. On the twenty-ninth day the wound was described as follows:

"Large ulcerating area on left chest; elevated margins, granulating floor covered with necrotic fibrous layer which seems attached only at edges. Rather sharp line of demarcation between necrotic tissues and peripheral granulating rim. The whole area is bordered by a peripheral brilliant pink zone. The whole is suggestive of an anaërobic infection." On this day a 1:2000 potassium permanganate solution was applied. On the thirty-first day the wound was exposed to the direct rays of the sun for five hours, and chloral hydrate, 5 per cent., and saturated solution boric acid dressings were applied to the infected area. On the next few days sunlight and potassium permanganate were used. On the thirty-fourth day the patient became somewhat irrational. The cultures of the pleural fluid at this time identified colon bacilli, Gram-positive cocci in pairs, and short chains which grew only anaerobically. The sunlight therapy caused considerable pain. On the forty-first day postoperative a débridement was done. At this time most of the infected area was removed and the Carrel-Dakin treatment started. The patient suffered a good deal for the next ten days, was very irritable, and required frequent sedatives.

On the fifty-second day the patient was again taken to the operating-room, and the sloughing area, which now measured almost 12 x 8 inches, was thoroughly débrided. After the return from the operating-room the patient's pulse went to 160 and was weak and "thready." He was slightly cyanosed. Camphorated oil, 5 per cent. glucose solution, by rectum, caffeine, sodium benzoate, digifolin, and elevation of the foot of the bed tided the patient over this severe state of shock. Carrel-Dakin treatment was continued. Morphine was now used occasionally to control the pain.

On the fifty-fourth day the patient was very weak and his speech was very incoherent at times.

On the sixty-first day an aerobic green forming streptococcus was obtained from the wound. The infected area was cauterized.

by stick silver nitrate. Hemoglobin had fallen as low as 57 per cent.

On the sixty-third day a slight hemorrhage was controlled by using adrenalin and thromboplastic packs, and later 650 c.c. of blood was transfused by the citrate method. This was followed by a mild chill and febrile reaction. The patient at this time was very nervous and at times irrational. The wound was treated by Dakin solution and was subject to occasional bleeding. Sunlight was allowed to shine on the wound, and various ointments, including glycerin and novocain, were applied to the wound. The pain in the wound was severe and necrotic sloughs were removed from time to time. Permanganate and then boric acid dressings were tried.

On the seventy-second day another blood transfusion of 500 c.c. of citrated blood was given, which was followed by an elevation of temperature to 103.2° F. Antiseptic powders were applied to the wound. The pain was severe at times and the patient was irrational.

On the eighty-second day the nurse described the patient as almost uncontrollable. He complained of pain constantly and was very nervous.

On the eighty-third day after admission and the rib resection I was asked by the attending physician, Dr. Balderston, to take charge of the surgical care of the case. At this time the patient's condition was very serious and his outlook had been considered as hopeless by some. The carbuncular infection now extended from within 2 inches of the left of the umbilicus to within 3 or 4 inches of the line of the spinous processes of the vertebræ. The upper level was the spine of the scapula and the lower within 2 inches of the crest of the ilium. The border was irregular in outline and 25 per cent. of the area was on the anterior chest wall and 75 per cent. on the posterior. In the center of this area, surrounding the site of original rib resection, was a patch of healthy skin some 3 x 5 inches. The floor of the ulcer was, for the most part, clean granulation tissue. The borders of the ulcer were of particular interest. These were elevated and thickened so that the skin and subcutaneous fat was from

2 to 2.5 cm in thickness. From the necrotic edges and through the eroded fenestrations of this border exuded abundant quantities of yellow pus. Necrotic yellow pieces of tissue were loosely or firmly attached to all places. The surface of the skin was red and inflamed for a distance of over an inch from the edge. This border was exquisitely tender. The temperature averaged 100° F and the pulse 100. The patient was emaciated and his morale greatly reduced by the suffering he had been through. Despite the large varieties of applications and the débridements the phlegmon was steadily advancing.

It was felt that a new plan of campaign would have to be adopted. The prime requisite of such a campaign would be the reduction to a minimum of the patient's pain. Co-operation and successful treatment would be impossible if the patient were continually hurt. Accordingly it was decided no procedures were to be done to the wound without the patient having first been anesthetized with nitrous oxid.

The second main consideration was the systematic *surgical* removal of the infected areas.

The third consideration was the proper application to make to the wounds, and on the advice of Dr. Albert E. Halstead, who was called in consultation at this time, unguentum Credé was chosen.

From the eighty-third day (6/12/23) to the one hundredth and eleventh day (7/10/23) ten dressings or débridements were done under nitrous oxid, occasionally supplemented by ether. These were done on the eighty-third, eighty-sixth, eighty-ninth, ninety-first, ninety-third, ninety-eighth, one hundred and first, one hundred and ninth, and one hundred and eleventh days.

At each of these débridements the necrotic infected skin borders were cut away with a scalpel. It was soon apparent that this entailed considerable blood loss, and after the third débridement a considerable hemorrhage occurred which was controlled only by adrenalin and thromboplastic applications, and thromboplastic injection, 10 c. c. by hypodermic. At the fourth débridement stick silver nitrate was used as a styptic.

to control hemorrhage. After the fifth débridement the hemoglobin had fallen as low as 60 per cent. and a blood transfusion by the citrate method of 500 c.c. was given by the writer.

While it was felt that great progress was being made in the surgical removal of the infected tissue, yet the danger from the loss of blood was great. The solution of the hemorrhage problem was finally found in the use of the electric cautery. After each stroke of the knife the raw oozing area was seared with the red-hot point of the electric cautery, and the coagulation produced effectively controlled the bleeding. This method was employed in all the remaining (five) débridements.

On the one hundred and tenth day the temperature, which had been normal, began to mount, and on the one hundred and thirteenth day reached 101.2° F. Suspicious, raised areas were explored without obtaining pus. The temperature averaged 100° F. until the one hundred and eighteenth day, when an abscess, which evidently originated in the lung, opened spontaneously and evacuated a large quantity of foul-smelling pus. The temperature dropped and this abscess healed quickly.

In the meantime the infection was steadily being gotten under control. The débrided edges of the phlegmon gradually became flat and normal. New epithelium began to grow across the large granulating areas.

Beginning the ninety-fifth day it became possible to do some of the dressings without anesthesia, the latter being employed only when it was necessary to débride infected tissue. On the one hundred and seventeenth day vaselin gauze was substituted for the unguentum Credé as a dressing. The patient began to eat and sleep, and his spirits and hopes were greatly increased. His weight rose from the neighborhood of 110 pounds to 128 on the one hundred and twenty-eighth day. On the one hundred and twenty-sixth day he was able to take an auto ride of one and a half hours.

He was discharged from the hospital with a few small granulating areas on the one hundred and thirty-ninth day. These areas healed within ten days at the patient's home and he went to the Canada woods to recuperate. When last heard from he

had resumed his former vocation in life, weighed 168 pounds, and was in excellent health and spirits.

### DISCUSSION

In the treatment of a major infection the surgeon occupies a position not unlike the commanding general or chief of staff in an involved and extended campaign. His problem is divided into the two great classes of "intelligence" and "strategy."

In the first class are included all knowledge of the strength, character and disposition of the enemy, and the nature of the field of battle; in the second the study of the best applications of his own forces and the final institution of offensive and defensive measures. He must know which arms of his service are the most effective in the defeat of the foe in order that he may encourage and emphasize them.

In the foregoing case the enemy is simply an army of pathogenic bacteria and the adventitious material incident to their attack. E. Lexer<sup>1</sup> calls attention to the importance of distinguishing between the tissue toxins and the products of the bacteria.

The study of offense and defense against this enemy requires, first, an examination into the nature of *inflammation*, which is the body's great protective reaction against infection. Hektoen speaks of inflammation as the "reaction of the tissues to local injuries calling forth protective measures; an imperfect pathologic adaption, often leading to consequences that are dangerous *per se* and may defeat its purpose." Warthin refers to inflammation as a "process complex essentially adaptive, protective, and reparative, called into action by a primary tissue lesion." It is in a sense an exaggeration of the normal body functions, and is of decided advantage to the attacked organism. According to the type of tissue lesions inflammations may be classified into (1) degenerative (as cloudy swellings) and (2) necrotic, which may further be subdivided into (a) simple, (b) diphtheric, (c) liquefactive (suppuration), (d) caseous, and (e) gangrenous.

<sup>1</sup> Amer Med Assoc, 80, 662, March 3, 1923

Lubarsch (in Aschoff's "Pathological Anatomie") does not include in the phenomena of inflammations fever, antitoxin formation, proliferation of leukocytes in the bone-marrow, and enlargement of lymph-nodules at a distance.

## THE FACTORS CONCERNED IN THE INFLAMMATORY PROCESS (AFTER WARTHIN)

### I. Tissue Lesion (Effects of the Injurious Agent).

1. *Disturbance of cell relation.* (Acute parenchymatous degeneration, cloudy swelling, etc)
2. *Solution of continuities.*
3. *Tissue degeneration.*
4. *Necrosis.*

### II. The Reaction (Protective and Defensive).

#### 1. *Chemotaxis.* (Bordet, etc.)

By means of diffusible substances wandering cells are attracted to and assembled at the point of injury (Metchnikoff).

2. *Leukocytosis.*—The increase in number of and the emigration of the white cells. In attempting to explain the reason for the increase in number of leukocytes the work of Hirsch<sup>1</sup> is very suggestive. He conducted a number of experiments in which living bacteria were injected intravenously in rabbits. As a result of his study he feels that it is suggested that diminution of the alkali reserve or the factors associated with this depression may afford the chemical stimulus necessary for the subsequent leukocytosis.

The leukocytes probably contain proteolytic ferments and bactericidal agencies which may be liberated under certain circumstances (Buchner). They doubtless digest fibrin and other proteins (Opie). Moreover, leukocytes have the power of forming a protective wall between the infection agent and the host.

Boud<sup>2</sup> believes that a capacity to elaborate a substance or substances closely allied to if not identical with glycogen is possessed by leukocytes, myelocytes, and certain epithelial cells. There are some facts which suggest an association be-

<sup>1</sup> Hirsch, E. F. J., *Infect. Dis.*, 28, 275, March, 1921.

<sup>2</sup> Boud, C. J., *Brit. Med. Jour.*, 2, 973, December 10, 1921.

tween the activity in glycogen formation and the resistance to infection

3. *Phagocytosis*.—The polymorphonuclear leukocytes in particular take up or ingest bacteria. They may in some cases, however, be destroyed by the bacteria.

4. *Vascular changes*:

- (a) Congestion.
- (b) Stasis
- (c) Marginal disposition of the leukocytes.
- (d) Diapedesis of white cells (Cohnheim.)
- (e) Diapedesis of red cells (Cohnheim).
- (f) Thrombosis.
- (g) Participation of the endothelium (Klebs, Heidenhain)

5 *Chemical protection* (protective properties acquired by the blood-serum)

- (a) Antibacterial (Alexius, Nuttall, etc.).
- (b) Antitoxic—substances which may be effective against the toxins liberated by the bacteria and those produced by the tissue destruction.

6 *Mechanical protection*:

- (a) Fibrin—which may prevent the spread of the infection
- (b) Cellular infiltrations—which also may impede the progress of the infection.
- (c) Granulation tissue.
- (d) Serous lymph exudate which may act as a diluent and irrigant

7 *Lymph-node Enlargement*.—The nodes contain bacteria and probably prevent their dissemination into other regions.

8 Influence of the nervous system (Samuels).

III. Resolution and Repair.

- 1 *Cell proliferation*
- 2 *Regeneration*
- 3. *Organization*.
- 4. *Cicatrization*.

A consideration of the general methods of treatment of pyo-

genic infections is now in order. It is incorrect to speak of "treating the inflammation," as inflammation is itself the foremost method of treatment of the infection.

## METHODS OF TREATMENT OF PYOGENIC INFECTIONS

### A. Physiologic.

#### 1. *General:*

- (a) Maintenance of nutrition.
- (b) Promotion of elimination by:
  - (1) Cathartics.
  - (2) Diuretics.
  - (3) Diaphoretics.
- (c) Rest.
- (d) Reduction of pain to a minimum—morphin if necessary.
- (e) Vaccines.
  - (1) Stock vaccines, a method in little repute at present.
  - (2) Autogenous vaccines, a method of value in long-standing infections which have a tendency to periodicity, as boils and furuncles. The vaccines must be made from a culture which is made with great care from the uncontaminated pus of the infection. The dosage of the vaccine is clinical, that is, it should be given in rapidly increasing doses until a mild reaction is obtained.
- (f) Foreign proteins. Killed typhoid bacteria, milk, peptone, etc., have been tried by intravenous administration in various infections in the hope that thereby the body's defenses against the invader may be increased. A febrile reaction with chills occurs. In one case at least<sup>1</sup> the writer felt that the foreign protein of the typhoid bacilli was somewhat beneficial. The

<sup>1</sup> Christopher, Frederick, Gas Gangrene in Civil Surgery: Report of a Case, *International Clinics*, 1922, vol. i, series 32.



use of foreign proteins in the arthritides have been more promising. (Miller, Jos. L., Peterson, etc.)

- (g) Blood transfusions—the blood of the donor probably containing bactericidal substances.

## 2 Local.

(a) Rest The placing of a badly infected extremity on a splint is often of no little value.

(b) Heat. The local application of heat in the treatment of infections has long been known to be of great value. The studies of Schäffer<sup>1</sup> are of great interest in this connection. Schäffer's method, as summarized by Adami, is as follows: "He takes a rabbit, and on one side introduces subcutaneously a catgut or silk thread as a seton, covering the wounds of entry and exit with collodion. If he wishes to study merely a foreign body inflammation the thread is introduced in a sterile condition. If he wishes, on the other hand, to set up one or other order of inflammation, the thread has been previously saturated with some irritant such as silver nitrate, carbolic acid, or suspensions of staphylococcus or streptococcus cultures, etc. Having introduced this subcutaneously on the one side, the process is repeated symmetrically in the like region on the other side, care being taken that the thread lies at the same depth on either side, since the reaction differs materially in muscular tissue and in the looser connective tissue of the subdermal layers and between muscles.

"Either immediately, or when the reactive process is well advanced, the lesion on the one side is treated by the application of heat in one or other form, or cold, the lesion on the other side being left untreated as a control. At any given moment the animal may be killed, the areas involved cut out, and the material prepared for microscopic examination. As a routine method sections are made at right angles to the long diameter of the thread."

<sup>1</sup> Quoted by Adami in Keen's Surgery, vol vi, p 28. Original articles *Der Einfluss unserer therapeutischen Maassnahmen auf die Entzündung*, Verlag von Ferdinand Enke, Stuttgart, 1907, also *Berliner Klin Woch*, 1910, p 817.

The heat caused extraordinarily powerful hyperemia and seemed absolutely to arrest the suppurative process. The defences of inflammation may be said to have been greatly accelerated. Schäffer places the upper limit of beneficial application of heat as not above 41° C. (106° F.) by moist heat and not above 45° C. (113° F.) by dry heat.

(c) Cold retards the course of the inflammatory process.

(d) Hypertonic dressings. These should have a greater molecular concentration than the blood-serum—the hypertonic solutions. They tend to cause an osmotic flow of the tissue lymph (and with it the obnoxious agents) into the dressings. The substance in solution is not of first importance, although boric acid, magnesium sulphate, and sodium chlorid are the more common ones. The “salt packs” of the British in the recent war are a further step in this method.

## B. Chemical.

1. *General.*—The very recent work of Young and others<sup>1</sup> in this direction is full of interest and stimulation. These workers have obtained very striking results on a limited number of cases of septicemia and local infection in the intravenous use of various dyes, as mercurochrome 220 soluble and gentian violet. The introduction of the latter causes a deep temporary cyanotic appearance. Apparently moribund individuals were apparently rescued by this method. (The administration of arsenicals has been advantageous in noma.)

2. *Local.*—Local applications are of value from two standpoints:

(a) Their sterilization of surface organisms.

(b) Their excitation of a local irritative reaction which may aid in the throwing off of the infection. Dakin's solution administered by the Carrell method, iodine, boric acid, alcohol, ether, silver and its salts, compound tincture of benzoin are among the most used applications.

C. *Surgical.*—The common purpose of all surgical pro-

<sup>1</sup> Young, Hugh, and Hill, Justina H., Treatment of Septicemia and Local Infections by Intravenous Injections of Mercurochrome 220 Soluble and of Gentian Violet, Jour. Amer. Med. Assoc., vol. 82, No. 9, p. 669, March 1, 1924.

cedures in the treatment of pyogenic and necrotizing infections may be said to be the facilitation of the removal of foreign bodies and of the débris incident upon the battle between the infecting organisms and the host and the removal of numbers of the organisms themselves

A basis for an outline of the surgical treatment is to be found in the very interesting comments of Martin.<sup>1</sup>

1 *The relief of tissue tension and pressure without* This is perhaps another way of saying the institution of drainage For this purpose wide and adequate incisions which extend to or through the limits of the infected tissue are necessary. To insure the continuance of drainage the margins of the incisions must temporarily be divulsed by some sort of packing which, while it holds the wound open, must not bar the egress of fluid exudate

2. *The mechanical elimination of necrotic and devitalized tissue—débridement.* This most important procedure is generally done with a scalpel or scissors. However, the actual cautery or the curet are occasionally used. Jopson<sup>2</sup> speaks very highly of the electrocautery knife in the treatment of carbuncles He feels that this method not only controls hemorrhage, but sterilizes the infected area which it traverses, and temporarily, at least, seals up the blood-vessels and channels surrounding the area excised

If necrotic and devitalized tissue be not removed it furnishes a great stronghold for the mobilization and propagation of bacteria Within the avascular tissue they are safe from the numerous blood-borne defenses of the host.

3 *The removal of foreign bodies.*

4 *The avoidance of stagnant fluids and exudates on the surface and dead spaces and the obliteration of incollapsible cavities* This heading includes the various methods which contribute to the disposal of the exudate.

(a) *Absorbent dressings.* Of these, gauze is by far the best In some cases the absorptive powers of the gauze is increased

<sup>1</sup> Martin, W, Ann. Surg, 68, 436, October, 1918

<sup>2</sup> Jopson, J. H., Surg Clin. N. Amer., 3, 93, February, 1923

by having it moistened with hypertonic solutions. These dressings must be changed as frequently as necessary according to the quantity of discharge

(b) Irrigations with sterile or mildly antiseptic solutions or the use of continuous baths. Having these solutions hot naturally gives them a double value.

(c) The light packing of non-collapsible cavities until they are gradually filled in by granulation tissue.

5. *The control of the exuberant products of repair:*

(a) Removal of excess granulation tissue.

(b) Removal of objectionable scars and keloid.

6. *Secondary suture.* This procedure being applicable to wounds which have been made sterile by appropriate treatment.

7. *Skin-graftings.*

8. *Dressings which facilitate epithelization:*

(a) Vaseline gauze.

(b) Gutta-percha strip.

D. *x-Ray Treatment.*—Dunham<sup>1</sup> reported the “successful treatment of 67 consecutive carbuncles by *x-ray*.”

A consideration of the above will show the wide choice of selection which the surgeon has in planning his campaign. There certainly are no hard-and-fast rules in the treatment of pyogenic infections. The methods of treatment must be suited to the individual case. Before instituting treatment the clinician has to inquire, as Muirs<sup>2</sup> remarks, (1) as to the nature and mode of introduction of the irritant and the damage done by it; (2) the extent of neutralization of the irritant and mode of removal of the same and of the damaged tissue; and (3) the process of repair.

In the case reported above practically all of the ordinary methods of treatment of pyogenic infections, including heat and hypertonic solutions, had been tried prior to the eighty-

<sup>1</sup> Dunham, *Amer. Jour. of Roent.*, 3, 259, May, 1916.

<sup>2</sup> Muirs, quoted by Adam in *Keen's Surgery*, vol vi, p. 18, or *Glasgow Med. Jour.*, vol. lxxii, 1909, 321.

third day postoperative, but the most effective ones had not been sufficiently emphasized.

In order of their importance the factors which contributed to the successful conclusion of this case were:

1. Reduction of pain to a minimum by anesthesia in dressings and morphin.
2. Surgical removal of necrotic and infected tissue.
3. Control of hemorrhage in the débridements by the actual cautery.
4. The application of unguentum Credé as an antiseptic to the dressings
5. Blood transfusions.

## CLINIC OF DR. J. P. GREENHILL

CHICAGO LYING-IN HOSPITAL

---

### THE DYSTROPHIA DYSTOCIA SYNDROME AS AN INDICATION FOR CESAREAN SECTION

Characteristics of the Dystrophia Dystocia Syndrome. Danger of Cesarean Section Not More than Danger from Very Difficult Vaginal Delivery. Transperitoneal or Cervical Cesarean Section is Operation of Choice. Reasons for This. Test of Labor Given These Patients. Six Illustrative Cases. One Illustrative Case Showing Bad Results of So-called Conservative Treatment.

SINCE there is at the present time a loud cry that too many cesarean sections are being performed, it may perhaps be rather hazardous to speak to you about extending the indications for cesarean section. Nevertheless it happens that even those who decry the increasing popularity of abdominal section, after having completed a very difficult vaginal delivery which resulted in much damage to the mother and the loss of or injury to the baby, not infrequently lament the fact that they did not perform a cesarean section. It is certainly true that one more often regrets not having done a cesarean section than having done one unnecessarily.

Now how can we tell in advance that we shall have great difficulty and perhaps lose the baby when we attempt delivery from below? It is, of course, unnecessary to emphasize that where a definite cephalopelvic disproportion exists, cesarean section is indicated, but there is a class of women whose bony pelvis, while not quite normal, are not in themselves sufficient to offer a real barrier to delivery from below, and yet were delivery attempted through the vagina in these patients many would come to grief.

At the Chicago Lying-in Hospital we have been attempting to recognize these patients before labor, although practically

all are given a test of labor. A certain group of signs give us a clue that trouble may be anticipated if we permit nature to take her course, or if we attempt to assist nature by delivering the patient per vias naturalis.

Naturally you will ask the question, How can you be sure that these patients cannot be delivered through the vagina with a minimum of danger to themselves and to their babies? It is true that we cannot emphatically say these patients cannot deliver live babies from below; for all of us have occasionally seen patients deliver spontaneously after we had thought cesarean section was the only means of delivery. However, practically all the patients in this group to which Drs DeLee and Horner gave the name of the "dystrophia dystocia syndrome," are given a test of labor. From our experience we can say definitely that disaster to the child and extensive lacerations of the mother will most likely occur in the majority of the cases of this special group if delivery is attempted through the vagina.

The characteristics of the dystrophia dystocia syndrome are as follows: The patient is usually a primipara who has married late or who conceived late in married life, and this in spite of the fact that she was anxious to become pregnant. If the patient is a multipara she will usually give a history of having had sad experiences in her previous pregnancies and labors. She may have had miscarriages or, what is more frequent, difficult labors, usually with children still-born as the result of difficult instrumental deliveries. In the patient's history we may find that there has been some menstrual disturbance, such as late onset of the menses, irregular menses, or dysmenorrhea. In general the sex-life of these patients may be as follows: Menstruation may be marked by dysmenorrhea. The first coitus may produce vaginismus and subsequent coitus may be associated with dyspareunia. When these women conceive it is usually late in life, and the pregnancy may terminate in a miscarriage or produce a mild toxemia. If the pregnancy goes to term there is dystocia at the time of labor.

The family history in these patients is of importance, for frequently it will be found that the patient is an only child,

never having had any brothers or sisters. If the patient has sisters who have been pregnant these sisters may have had difficult labors with still-births.

Examination of some of these patients will reveal certain masculine characteristics or evidences of hyperpituitarism. There may be a wide distribution of hair, a masculine form of the face and extremities, and a masculine pelvis, with thick, heavy bones and a narrow pubic arch. In general you will find the available space in the pelvis slightly contracted, but not sufficient to make one think of a difficult labor from that one cause alone. Most of the patients are rather short and stout. They have short forearms and a short stubby fingers, but large wrists and ankles. Most of the patients go overterm. At the time of labor we find that the pains are usually weak and irregular and may last for days without any progress being noted. The head usually presents as an occiput posterior and it remains high in the pelvis. Not infrequently the breech is the presenting part. The membranes often rupture early in labor and the cervix dilates very, very slowly.

Because there is little progress despite definite uterine contractions, and the physician makes repeated calls and examinations without exhibiting much enthusiasm as to the way things are progressing, the patient's psyche becomes disturbed. These patients are usually highstrung anyway.

Attempts to hasten labor with medicinal or mechanical means may be successful in stimulating labor-pains, but usually make the end-result more disastrous. These patients frequently have only one pregnancy, and it is important that you deliver a live baby, especially because the added risk to the mother is slight.

Now you must not forget that a difficult delivery from below, with its attendant lacerations, hemorrhage, and traumatism is by no means without danger to the mother. Hence, while the danger from abdominal delivery is usually greater than delivery from below, when we face the probability of a very difficult vaginal delivery in a case where it is essential that we deliver a live baby (which means nearly every case), the delivery



from below with its most probable damage to both mother and baby does not really outweigh the advantages of a cesarean section

In referring to cesarean section we refer to the transperitoneal or cervical type of operation (laparotrachelotomy), for this is definitely less dangerous than the classic cesarean section. There is a minimum of complications after the cervical type of operation, for the patients seldom have nausea or vomiting, there is practically no gastric or intestinal distention, and almost no "gas-pains." The danger of peritonitis is practically nil in clean cases and even in suspicious cases. The lack of complications is due to the fact that the incision is made in the cervix, which resists infection better than the body of the uterus, just as the pelvic peritoneum resists infection better than the peritoneum of the upper abdomen. The uterine incision is at rest, hence the uterine contractions (after-pains) do not squeeze the lochia through the incision. Even were this to occur the lochia would be under the peritoneum, between the cervix and the bladder, where it could easily be reached through the cervix, between the cervix and bladder (anterior colpotomy), or by opening the lower end of the abdominal incision. Hence the lochia or even infection if there be any, is prevented from reaching the peritoneal cavity. The intestines and omentum are practically never seen or handled during the operation, and this accounts for the lack of abdominal symptoms following the operation. By means of a suction pump, which removes the liquor amnii, the latter is prevented from pouring into the peritoneal cavity. The possibility of rupture of the scar in subsequent labors is reduced to a minimum, for only 4 cases of rupture of the uterus have been reported following many thousands of these operations done in various parts of the world. In a series of over 260 cervical cesarean sections performed at the Chicago Living-in Hospital only one mother died.

Recently we have been doing the low or cervical cesarean sections (laparotrachelotomies) under local anesthesia, with great success. This eliminates almost entirely the only real complication which may occur after this operation, namely,

pneumonia. Shock, which sometimes follows an ether anesthesia, is likewise avoided. There is no more difficulty in performing a cervical cesarean section under local anesthesia than there is in doing a classic cesarean. I shall now read you a few case histories of patients who exemplify the dystrophia dystocia syndrome.

**Case I.**—Mrs. A. B., a tertipara, aged twenty-seven, gave a family history of dystocia. Her mother died during the third labor and her two sisters had had very difficult instrumental deliveries. The patient's first labor (in 1917) was terminated by a high forceps delivery. The child was severely injured and died ten days after birth. The patient suffered extensive lacerations of the perineum. In 1919 the patient was again pregnant, and this time also labor had to be terminated by high forceps. The extraction lasted one and three-quarters hours and the child lived. The perineum was again lacerated, and in 1921 this was repaired by operation.

The expected date of confinement of the present pregnancy was July 28, 1922. The patient went past term, and on the sixteenth day after the calculated date of confinement I saw her in consultation. She was 5 feet, 1 inch in height, but weighed 188 pounds. The general examination was negative except for short forearms and short, thick fingers. The external pelvic measurements were I. Sp.  $27\frac{1}{2}$ , I. Cr.  $28\frac{1}{2}$ , I. Tr. 35, and Baude-locque 20 cm. The diagonal conjugate measured between  $11\frac{1}{4}$  and  $11\frac{1}{2}$  cm. and the position was occiput left posterior. On bimanual examination the head could not be made to enter the pelvis. The blood-pressure and urine were normal. On two occasions castor oil and quinin had been given, without effect.

Because the patient was presumably sixteen days overdue (the baby weighed 3820 gm. or 8 pounds, 7 ounces), because the head could not be made to enter the pelvis, and because of the history of two previous difficult instrumental deliveries, I performed a cervical cesarean section without waiting for labor-pains. Both mother and baby left the hospital in good condition on the eleventh day.

forceps The baby was then delivered with moderate difficulty after making a mediolateral episiotomy. The child, which weighed 3675 gm (8 pounds, 2 ounces), was asphyxiated, but after much effort was resuscitated with a tracheal catheter. Examination of the birth canal after delivery revealed an extensive laceration of the anterior vaginal wall. Immediately following delivery the patient had a violent chill and the temperature rose to 104.6° F. Subsequently a vesicovaginal fistula developed. The baby showed evidence of cerebral hemorrhage and had a number of convulsions.

Both mother and baby, after having had a stormy convalescence, left the hospital on the twenty-sixth day after the delivery.

Comment here is unnecessary. Fortunately everything turned out well, for examination a few weeks later showed the vesicovaginal fistula to be entirely healed and the baby was normal in every respect.

This patient returned a year later pregnant, and was delivered by a cervical cesarean section.

To recapitulate, the chief characteristics of the dystrophia dystocia syndrome, which briefly we designate as the D. D. S., are as follows: The patient conceives for the first time relatively late in life or has had sad obstetric experience previously. She is usually a heavy-set woman with masculine and hyperpituitary characteristics. The available space in the pelvis is somewhat smaller than normal and the extremities are short. There may be a family history of dystocia and the patient's own history may elicit abnormalities of the sex-life. The patient usually goes beyond term, and the fetal head, which is in an occiput posterior position, remains above the pelvic inlet even after many hours of labor. The membranes may rupture before the onset of pains, and the latter are usually weak and irregular. When delivery is attempted from below the result is usually disaster to the child and injury to the mother. In view of this danger, and because many of these patients may never become pregnant again, it is advisable to do a cesarean section to deliver a living and uninjured child.

## CLINIC OF DR RALPH BOERNE BETTMAN

MICHAEL REESE HOSPITAL

---

### CHRONIC EMPYEMA

Presentation of a Case, with Discussion of Some Important Points in the Treatment.

I AM going to present in my clinic today only one case—a case of chronic empyema. I hope by the discussion of this case to draw your attention to many interesting features in this disease

Mr. O. R., a man of fifty, was taken sick about a year ago with bronchopneumonia. He developed an empyema, which was treated by the closed method, and made a prompt recovery. He left the hospital with his air-tight drainage-tube in place and for some time continued treatment at home. Finally, after smears taken of the aspirations of his cavity were negative for bacteria and all his symptoms having long since abated, he was pronounced cured and the tube removed.

Here I wish to emphasize an important point: *It was a mistake to remove the drainage-tube without an x-ray examination to prove that the empyema cavity was obliterated*, even though he was free from all symptoms and his pleural cavity was apparently sterile.

It is very important, especially in adults, to be sure that no unobliterated cavity is left when the thoracotomy wound is allowed to close. In children and occasionally in young adults an apparently sterile empyema cavity will close spontaneously. The lung expands, the remaining air is absorbed, and the cavity is obliterated. This, however, is the exception and not the rule. *The rule is that it is inadvisable to discontinue empyema drainage in the presence of an unobliterated cavity.* Before removing the

drainage-tube in the case of an empyema I allow a 12 per cent. solution of sodium bromid to run into the cavity under very low pressure and then x-ray the chest. The amount of fluid which will flow into the cavity can be accurately measured. The x-ray plates disclose the shape and anatomic position of the cavity I do not favor bismuth paste. In some cases it works admirably, but in others I have felt that the small particles of paste which were not expelled acted as foreign bodies and prolonged the suppuration. Sodium bromid is opaque to x-ray, is easily obtainable, flows readily, can be siphoned or flushed out of the cavity, and is not toxic. Because of the thickened pleura which is usually present in any case of empyema percussion and auscultation alone are not reliable, nor is x-ray, without filling the cavity

Our patient reacted, as would the overwhelming majority of adults, with a closed unobliterated cavity. Within a few weeks he began to feel sick again, developed an intermittent afternoon temperature, and soon had an outspoken recurrence of his empyema

The question arises as to whether his cavity was actually sterile. And the most likely answer is that it was not. It is not difficult to conceive of an irregular-shaped cavity in which a small recess harboring bacteria is closed off from the main cavity, so that the effluvia of the main cavity on three successive days may readily be sterile. From this source the unobliterated cavity may be reinfected.

Another question which might occur to you is, Why should these left-over bacteria be especially harmful in the presence of an unobliterated cavity? This question cannot be answered directly. This much we know, that wherever there remains in the body a rigid cavity, be it an osteomyelitic cavity *in bone* or be it a dead space such as occurs, unless care be taken, in the axilla following a radical removal of the breast, there an infection is apt to occur and be difficult to control

Another factor may be involved. Notzel has shown experimentally that the normal pleura is very resistant to bacteria as long as its two layers—parietal and visceral pleura—are

in contact, but that if air be introduced into the pleural cavity so that a pneumothorax is produced, then the same dosage of bacteria produces an infection—empyema. This is a very interesting and important finding.

I saw Mr. O. R. when he was admitted to the hospital the second time. He was very ill and profoundly septic. Under local anesthesia a tube was placed in his chest by the trocar method. The cavity was irrigated with Dakin's solution. He was then put on the usual routine adopted for acute empyema cases treated by the closed method, to wit:

The contents of the cavity were aspirated every two hours and Dakin's solution was reinjected, injecting about one-third as much Dakin's solution as the amount of pus aspirated. The Dakin's solution was used not only for the purpose of sterilizing the cavity, but more especially to dissolve the fibrinous exudate. Besides this he was given a pair of Wolff blow-bottles and told to empty one bottle every hour during the waking hours. Three times a day he was given a short series of calisthenics consisting chiefly of breathing exercises.

It is surprising how often chronic empyema is amenable to such treatment, and I urge you to try out this simple method before taking more radical procedures.

The temperature quickly subsided, and within a week the patient was again free from all symptoms. The cavity was now filled with a 12 per cent, sodium bromid solution and this roentgenogram (Fig. 277) taken. You can see a cavity which extends from the fifth rib down to the tenth. It seemed improbable, judging from the size of the cavity and the thickness of the pleura, which had to be traversed before the trocar reached the cavity, that aspiration and irrigation would be of avail in this case; still, however, it was decided to try this method of treatment first.

As you know, chronic empyema is often complicated by bronchial fistulæ. The presence of these fistulæ is a contra-indication to the dakinization of the cavity only when, as frequently happens, the introduction of the solution produces violent spasms of coughing. Although once or twice Mr. O. R.

claimed that he tasted the Dakin solution, yet at no time did he have a paroxysm of coughing after its injection.

After three weeks another radiogram of the cavity filled with sodium bromid solution was taken. There was practically no change in size or shape, so we proceeded with operation.



Fig 277 —Roentgenogram showing cavity in chest extending from fifth to tenth ribs.

*In operating for empyema I attempt to do two things—first, obliterate the cavity; second, cover the defect with skin. The operation I performed on Mr. O. R. is typical of the operation I use for chronic empyema with large cavities. It is not original, but contains features described by Schede, Estlander, Ransohoff, Beck, Eggers, and others. It can be done in as many stages as desired. In this patient the two-stage operation*

was employed. At the first stage a horseshoe-flap, approximately covering the roof of the cavity, was lifted. This flap contained skin, subcutaneous tissue, and muscle. Segments of the sixth, seventh, eighth, and ninth ribs overlying the cavity were removed. The skin-flap was then brought back into place

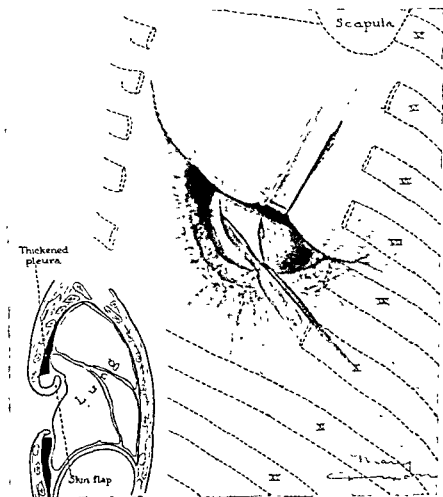


Fig. 278.—Drawing showing technic of operation.

and anchored with a few heavy silk sutures and the patient returned to his room (Fig. 278)

Three days later the second stage of the operation was done. The flap was lifted and a free incision was made through the parietal pleura, disclosing a large irregular walled cavity



which extended upward under the fifth rib and down to the ninth. The parietal pleura was 1 inch in thickness; it was tough, almost cartilaginous. The visceral pleura looked like an aponeurosis, being about the same thickness as the iliotibial band and resembling it in appearance. It was insensitive and could be cut or stripped from the underlying lung without pain. A portion of the fifth rib was resected. The entire parietal pleural covering of the cavity was removed much as one might cut away the meat of a coconut after a part of the shell had been broken off. Bleeding was controlled with forceps and hot packs. An attempt was made to decorticate the lung, but although this was possible in some places, in others it was not.

In these places where the fibrous covering could not be removed incisions were made into it. It is remarkable how much a lung which has been held down for months by a thick fibrous envelope will expand as soon as the envelope is cut. In the case of Mr. O. R. the lung started to expand immediately, spreading every decorticated patch. The cavity was inspected for bronchial fistulæ. None was found. Had I found any my procedure would not have varied greatly. Small fistulæ I might have cauterized with the actual cautery, hoping to hasten closure by destroying the rigid walls. Large fistulæ I would have left alone, knowing that eventually they would close spontaneously as the lung expanded and the cavity contracted.

A bronchial fistula acts as a drain in an otherwise closed cavity much as the cloacæ in an osteomyelitis. When the cavity is opened widely the fistulæ commence to close spontaneously.

I now turned my horseshoe-flap into the cavity and stitched it into place. It covered the dome of the cavity and the upper third of the inner wall. The cavity was lightly packed and the patient returned to his room. The convalescence was smooth and steady. The wound was dressed twice a day. Calisthenics and blow-bottle exercises were carried out with utmost regularity.

A word or two regarding the anesthetic might not be amiss. For the type of operation I have here performed a local anesthetic would be the method of choice. It is not easy, however, to

carry out this method in all cases. Again, some patients are so frightened by the tugging of the retraction and by the sound of the cracking of the ribs that in spite of the absence of pain they require a general anesthetic. For general anesthesia I prefer nitrous oxid and oxygen. I have not had sufficient experience with ethylene to make any comments. Nitrous oxid and oxygen are given with the usual tanks and mask. No matter what thoracic procedure I am undertaking, no matter whether or not local anesthesia is procuring desirable insensibility, I always have at hand the nitrous oxid and oxygen apparatus to provide a means of artificial pulmonary insufflation. It is often impossible to predict the firmness of the adhesions which hold the lung, the extent to which the lung will collapse, and the extent to which this will affect the patient. Therefore, although rarely needed in this type of operation for a chronic empyema, it is a wise precaution to have at hand the means to inflate the lungs. When local anesthesia is used the skin and subcutaneous tissues are infiltrated in the line of incision. The periosteum and the parietal pleura are anesthetized by blocking the intercostal nerves. This is done by paravertebral injections, injecting at the angle of the rib and just under the rib. It is necessary to inject several interspaces above and below the area of operation, as the areas of distribution of the intercostal nerves overlap. The visceral pleura and the lungs are insensitive to pain. In the case of Mr. O. R. I performed the first stage under local. Although he had no pain, the pressure from the retraction and especially the sound and vibration of the rib cutting were so unbearable for him that I gave him a general—that is, gas oxygen—anesthesia for the second stage.

This is now the seventh week after operation. The defect is less than one-half what it was immediately after operation. This is due to two factors—the pulling in of the skin margins by cicatrization and the expansion of the lung. The flap, as you see, took well. The surface of the lung, which at operation was irregular, has smoothed out. I can peel off the fibrinous exudate which has covered the lung. This I have been doing every week. As you see, it pulls off easily. In a week or so I am going to

take pinch-grafts from the skin of his back and place them on the lung surface. This will expedite the epithelization of the shallow defect.

The man, as you can see, is well and can work. His wife changes the dressings for him in the morning before he goes to work and in the evening before retiring. The discharge is very slight.

I have presented the case in detail because I want to emphasize especially the following important points in the treatment of chronic empyema:

- 1 Chronic empyema can be prevented in a large number of cases by care in the treatment of acute empyema. Remember, a closed unobliterated cavity, even though apparently sterile, will most probably become reinfected and lead to recurrence.

2. A case of acute empyema should not be pronounced cured unless it has been proved that no cavity remains.

- 3 The shape and extent of an empyema cavity can be clearly determined by filling that cavity with 12 per cent. solution of sodium bromid and then x-raying the case.

4. Many cases of chronic empyema can be cured by drainage and careful dakinization plus the use of blow-bottles and calisthenics.

- 5 After conservative treatments have proved inefficient radical operation must be resorted to. The aim of all radical treatment is the obliteration of the cavity.

6. The operation I use is, in brief: Preserving of a skin-flap, exposing the entire cavity by resection of ribs and excision of the thickened parietal pleura, decortication of the compressed lung where possible, dealing with fistulæ by cautery or allowing them to close spontaneously, turning in the skin-flap, and allowing the wide-open defect to heal by cicatrization.

## CLINIC OF DR. MAURICE A. BERNSTEIN

MICHAEL REESE HOSPITAL

---

### STABILIZING OPERATION FOR PARALYTIC FEET

Presentation of 2 Patients on Whom the Stabilizing Operation was Performed. Technic. Results Obtained. Report of the American Orthopedic Association on the Value of This Operation.

THE first question invariably asked when one is confronted with a paralytic foot is, What operation will correct the deformity? second, What assurance is there of a successful result? and third, How long will the patient be incapacitated as a result of the operation? We are fortunate to be able to show you at this time 2 cases which call for standard operations for the relief of deformities resulting from infantile paralysis, and although the deformity in the first case is not due to acute poliomyelitis, the effects upon the lower extremities is practically the same.

Case I.—*History*.—Boy aged eighteen (Fig. 279). When this patient was nine years old he entered Michael Reese Hospital for a spina bifida condition. There was at that time a notation that the patient was rapidly failing in ability to walk due to muscular weakness. There was not sufficient deformity of his feet to require operation. He had partial incontinence of urine and feces. On December 8, 1913 the spina bifida was operated upon in another hospital. He was readmitted to Michael Reese Hospital in August, 1914, and a suprapubic cystotomy was done by Dr. Eisendrath for relief of urinary retention. He entered the hospital again July, 1915 with a trophic ulcer on the right foot and thigh. There was at this

take pinch-grafts from the skin of his back and place the lung surface. This will expedite the epithelization shallow defect.

The man, as you can see, is well and can work. He changes the dressings for him in the morning before he goes to work and in the evening before retiring. The discharge is slight.

I have presented the case in detail because I want to emphasize especially the following important points in the treatment of chronic empyema:

1. Chronic empyema can be prevented in a large number of cases by care in the treatment of acute empyema. Remember a closed unobliterated cavity, even though apparently sterile will most probably become reinfected and lead to recurrence.

2. A case of acute empyema should not be pronounced cured unless it has been proved that no cavity remains.

3. The shape and extent of an empyema cavity can be clearly determined by filling that cavity with 12 per cent. solution of sodium bromid and then x-raying the case.

4. Many cases of chronic empyema can be cured by drainage and careful dakinization plus the use of blow-bottles and calisthenics.

5. After conservative treatments have proved inefficient radical operation must be resorted to. The aim of all radical treatment is the obliteration of the cavity.

6. The operation I use is, in brief: Preserving of a skin-flap exposing the entire cavity by resection of ribs and excision of the thickened parietal pleura, decortication of the compressed lung where possible, dealing with fistulæ by cautery or allowing them to close spontaneously, turning in the skin-flap, and allowing the wide-open defect to heal by cicatrization.

*Examination and Findings.*—Left leg: Achilles' jerks absent. Right knee-jerk absent. Left knee-jerk diminished. Moderate atrophy of left thigh and weakness of both quadriceps femoris, but he can extend both legs. Paralysis of peroneus longus and tibialis posticus, so that there is a loss of abduction of the ankle. There is a little motion present in the tibialis anticus, fair strength in the extensor communis digitorum and in the extensor longus hallucis. He can, therefore, adduct the foot and extend his toes. There is a marked weakness in the plantar muscles. There is, in addition, a weakness of the adductor muscles so that there is a tendency toward eversion and abduction of the thighs.

*Right Foot.*—Weakness of peroneus longus and tibialis posticus, fair strength in the common extensors and in the tibialis anticus. Both feet are swollen, cold, and cyanotic. The sensory loss of the right extremity includes the fourth and fifth lumbar and the first, second, and third sacral. On the left there is involvement of the second, third, fourth, and fifth lumbar, and first, second, and third sacral. Both feet are markedly deformed in equinovarus and an exaggerated cavus.

*Comments.*—You will note from the history that this boy has a progressive compression of the cord involving the roots of the lower lumbar and sacral plexus. This may be a cicatricial constriction at the seat of the operation for the closure of the spina bifida. In view of the fact, however, that he has no bladder or rectal trouble, and since the boy refuses an operation for the liberation of the nerves involved, the operation will be postponed for some later date. The deformity of his feet will not become rectified by any operative work that may be done upon his spine. These deformities are fixed. All this boy desires is a pair of feet that he can walk upon. I am quite certain that this can be accomplished. You will note from the history that the muscles around the hip-joint are weak, and as a result he throws his legs from his pelvis in a somewhat similar manner to the action of a wooden actor. He must depend upon gravity to aid him in placing his feet upon the ground. There is considerable motion in his abductors and external rotators of the thighs, so that he has a fairly good control of his legs. His feet are so

deformed, however, that he is unable to place them upon the ground to permit a sufficient treading surface.

Our aim, therefore, is to straighten his feet for him and stabilize them so that he will have a firm support. Tendon transplantation is out of the question in his case. You will note that the peronei muscles are paralyzed so that he cannot abduct his ankle. The little power he has in his tibialis anticus muscle only tends to turn the foot in and increases the deformity. Transplantation of the extensor longus hallucis to the outer side of the foot or transplantation of the tibialis anticus will not hold the foot out. The action in either muscle is not sufficient to exercise an influence upon the ankle-joint. Tendon transplantation in a case of this sort would be a complete failure.

The operation of choice in a case of this kind is one that will ankylose the joints which permit lateral and downward motion of the foot. The operation which fulfils this demand is horizontal transverse section of the foot as advocated by Gwilym Davis. The principal of this operation consists in the taking out of a section of the bony framework of the foot, passing entirely through the tarsus from the junction of the os calcis and astragalus, and emerging in front on the anterior surface of the cuneiform. This operation leaves the foot with a movable ankle-joint, but prevents lateral motion. Before doing this operation one must overcome the contractures which are present in the soft structures. You will notice that the heel is drawn up by the contracture of the tendo achillis. You will also observe that the plantar fascia is tense and shortened, causing the large toe to approximate the heel. This fascia will have to be cut, and can best be accomplished by the method of Steindler.

*Operation*—The legs are prepared from above the knee to the toes by thoroughly cleansing in the usual manner—soap and water, followed by alcohol, ether, and iodin, care being taken to iodinize between the toes. A constrictor is placed around the calf to the knee. The patient is placed upon his side. The first procedure is to lengthen the tendo achillis. This is done subcutaneously. A small incision is made parallel with the tendon. This is just large enough to permit the en-

trance of a long-bladed tenotome. The tenotome is carried along the tendon which is put on a stretch by strongly dorsiflexing the ankle. You can feel the tenotome as it passes along the surface of the tendo achillis—the point of the knife can be felt under the skin, and is about 1 inch below the point of entrance. The blade is now reversed so that its cutting edge is upon the surface of the tendon and about in the midline. The blade is thrust through the tendon and carried up so that the tendon is split. A small bladed tenotome is now inserted through the skin opening and the outer half of the tendon cut across. A small incision is now made below and the small bladed tenotome inserted, and the tendon is cut through half its inner border. You will note that the long incision in the longitudinal direction of the tendon together with the two small transverse incisions correspond to the letter Z. The foot is now forcibly dorsiflexed, causing the cut surface of the tendon to slip, and thus lengthening the tendon; we will put a catgut stitch in each one of these small incisions and cover it with a little cotton collodion. Now, you see, the heel is brought down quite a bit. We will now cut the plantar fascia. We make a longitudinal incision on the inner side of the foot along the outer edge of the plantar fascia. You can feel the tense outer border of this fascia. We introduce a chisel along the os calcis and strip this fascia with all its attachments from the bone. These two steps—the lengthening of the tendo achillis and stripping of the plantar fascia from its attachments to the os calcis—permit eversion of the foot. You will note that there still is a tendency for the foot to assume the club position, and that the cavus or hollow of the instep is still exaggerated. In order to assure a corrected position we must overcorrect the deformity. This principle must be borne in mind when correcting any deformity. How are we going to accomplish this? We are going to ankylose the midtarsal joints, that is, the calcaneocuboid, the astragaloscaphoid, and the subastragaloid joints. Further, we are going to remove enough of the articulating surfaces from these bones so that we will obtain a transverse horizontal section of the foot. We now make an incision below and behind the external malleolus and carry it



from Fig. 281 that we have accomplished a fairly good correction.

**Case II.**—Miss R. C., aged nineteen years (Fig. 282).

*History.*—Patient states that deformity of her right foot has been present since she was two years old, at which time she had some sickness not known to her. There was some deformity in her left foot, but this did not take definite form until she became nine years old. An attempt was made in Paris to correct the



Fig 282 —Case II. Shows left foot before operation. Dimple on back of leg shows where the tendo achillis was cut some years ago. Note the instability of the forefoot. The plantar fascia is considerably contracted, producing the hollow foot.

deformity of both feet, but the operation was not successful. In the past few years the deformity has been getting much worse, but she is able to walk with the assistance of a cane.

*Right leg* is 1 inch shorter than the left. Quadriceps femoris shows some weakness. Considerable atrophy of thigh. Hamstrings are also weak. Abduction and adduction of thighs good. Gastrocnemius group is paralyzed—a very slight motion in toes, none in tibialis anticus.

*Diagnosis* —Flail foot.

*Left Leg.*—Peronei paralyzed. Tibialis anticus good. Extensor hallucis longus fair, extensor digitorum communis fair, plantar muscles good, gastrocnemius group good. Plantar fascia contracted, drawing the foot up in cavus and equinovarus. Hamstrings normal. Extensor abductors good.

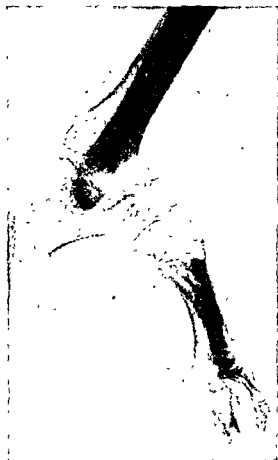

Fig. 283.—Roentgenogram taken some months after astragalectomy. Note the wrong position of the malleoli in contrast to Fig 284. This foot is no better than before the astragalus was removed. It shows the malleoli resting upon the os calcis, exaggerating the calcaneus deformity.

Right foot was operated May 11, 1922. An astragalectomy was accomplished at that time. Left foot was operated July 11, 1922. Arthrodesis of the calcaneocuboid and stripping of plantar fascia.

from Fig. 281 that we have accomplished a fairly good correction.

**Case II.**—Miss R. C., aged nineteen years (Fig. 282).

*History.*—Patient states that deformity of her right foot has been present since she was two years old, at which time she had some sickness not known to her. There was some deformity in her left foot, but this did not take definite form until she became nine years old. An attempt was made in Paris to correct the



Fig 282 —Case II Shows left foot before operation. Dimple on back of leg shows where the tendo achillis was cut some years ago. Note the instability of the forefoot. The plantar fascia is considerably contracted, producing the hollow foot.

deformity of both feet, but the operation was not successful. In the past few years the deformity has been getting much worse, but she is able to walk with the assistance of a cane.

*Right leg* is 1 inch shorter than the left. Quadriceps femoris shows some weakness. Considerable atrophy of thigh. Hamstrings are also weak. Abduction and adduction of thighs good. Gastrocnemius group is paralyzed—a very slight motion in toes, none in tibialis anticus.

*Diagnosis* —Flail foot.

tiquity. Although the silk ligament may hold up an occasional drop-foot, it does not prevent the development of lateral distortion of the foot, and in young children does not allow for the growth of the leg.

Tenodesis, or fastening of tendons to the tibia and fibula by the methods of Putti, Gallie, Codivilla, was also received with little favor. Gallie is responsible for developing and popularizing this operation. The few cases I operated by means of this method turned out quite satisfactorily. It is important to denude the tendon of its sheath and scarify it, so that the bone cells can permeate the tendon and so definitely fix it to the groove into which it is placed. Most of the failures from this method are due to slipping of the tendon and are a result of a faulty technic.

In regard to selecting cases for operation the commission is convinced that patients having paralytic talipes calcaneus, talipes calcaneovarus, and flail or dangle foot, with or without the additional deformities of varus or vagus, are suitable subjects for the operation of astragalectomy and transverse horizontal section, and that patients having active calf muscles are not suitable for these operations.

The operation which seems to fulfil the requirements of stabilizing a flail or dangle foot is astragalectomy, an operation developed by Whitman to relieve a calcaneus or calcaneocavus deformity, and it is this type of operation which was performed on this patient upon the right foot in 1922.

You will recall that she had little power in the muscles below the knee. The triceps suræ was completely paralyzed, so that she had a calcaneus deformity. You will note from the x-ray (Fig. 283) that the condition was not relieved by the operation, and you can plainly see why that failure occurred. You will note that the tibial and fibular articulations rest upon the os calcis as it did before the astragalus was removed. The reason for this failure in position is due to the fact that the foot was not brought backward. When the astragalus is removed the malleoli must be placed in grooves made in the calcaneocuboid on the outer side and the calcaneoscaphoid on the inner

side of the foot (Fig 284). She was reoperated by me for correction of this error, and you will see from Fig. 284 that her foot assumes a nearly normal position.

*Operation.*—Right foot We place an Esmarch constrictor above the knee. This will make our field of operation bloodless. We begin our incision about an inch above the external malleolus midway between it and the tendo achillis, passing downward around the malleolus across the dorsum of the foot to the external surface of the head of the astragalus (Fig. 285).

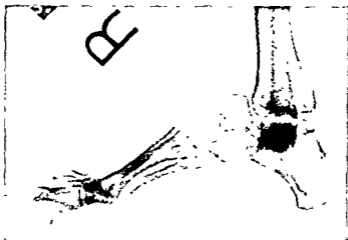


Fig. 284.—Same as Fig 283. Foot after second operation. The astragalus is removed and the malleoli are displaced forward on the foot, fitting in grooves made in the calcaneocuboid and calcaneoscaphoid bones.

We can now see the peronei tendons as they pass behind the external malleolus. We open the sheath of these tendons and you will remember that the peroneus longus and peroneus brevis occupy the same sheath at this point. We now cut down along the sheath as far as the incision will permit and section the tendons as low down as possible. We now retract these tendons out of our way. By means of scissors we now cut the astragalocalcaneal ligament, the interosseous ligament, and the anterior fasciculus of the external lateral ligament. The foot can now be strongly abducted and rotated inward. The head of the as-

tragalus can now be freed from its attachments to the navicular. We now grasp the head of the astragalus, pulling it outward and further abducting the foot. With a knife we swing around the inner surface of the astragalus, cutting the internal lateral liga-

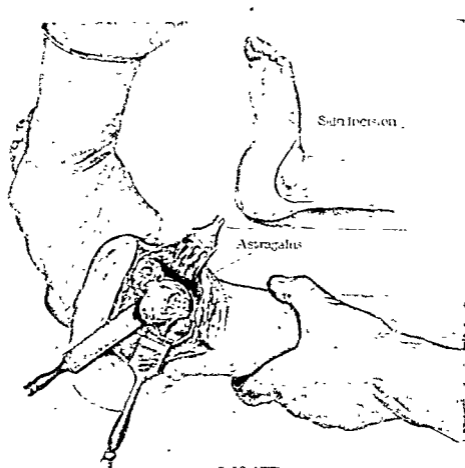


Fig. 285.—Two steps in astragalectomy. Small figure illustrates the incision and character of the foot in calcaneovalgus. Large figure shows the astragalus about to be removed. Note the position of the assistant's hands. The foot is firmly grasped and rotated inward, aiding in dislocating the astragalus. After the astragalus is removed the same hold is maintained and the foot is displaced far backward.

mentous attachment and freeing the attachment to the scaphoid we were unable to reach with the foot abducted. Now the astragalus is popping out (Fig. 285); we will cut the under surface to completely free it, and here we deliver the entire as-

use his foot, even with the aid of a brace, he is not only justified, but it is his duty to operate at any age." Dr. Willard in discussing the report stated that bony arthrodesis should be done as soon after the seventh year of life as the prognosis is thoroughly established and all the power that can be obtained has been obtained.

Ryerson,<sup>1</sup> who is a staunch advocate of the so-called "triple arthrodesis" operation for stabilization of the joints of the foot, in a thoughtful paper on the subject claims for this operation "extremely satisfactory results," and says further that the operation is recommended as safe and logical. When a partially paralyzed foot has been stabilized in this way, that is, by arthrodesis, tendon transplantation can be done to provide motion in the ankle-joint with the certainty that disabling lateral deformity will not occur, and gives further justification of the operation by stating that the essential instability of the imperfectly controlled mediotarsal and subastragaloid joints is one of the most frequent causes of deformity and disability in paralysis of the leg.

Let me emphasize in conclusion that a foot upon which a transverse horizontal section or an astragalectomy is accomplished should be displaced as far backward as is possible, and that it is advisable to place and maintain the foot in slight equinovalgus and a well-fitted brace worn until the desired correction is assured. When an arthrodesis is performed a brace should be worn for a period of one year after the cast is removed. This is particularly so in children under ten years of age.

<sup>1</sup> Journal of Bone and Joint Surgery, July, 1923

